

Dental Portfolio

Dr. Kashmiri Pawar

BDS, MDS, Paediatric & Preventive Dentist

+971-505679198

✉ drkashmirapawar@gmail.com



A seasoned Pediatric Dentist with a passion for delivering exceptional oral care, I bring over 7+ years of experience and a unique blend of expertise, having completed my MDS in Pediatric and Preventive Dentistry from Rajiv Gandhi University of Health Sciences, Karnataka (2021) and BDS from Dr. D.Y Patil - Deemed University (2016).

As a former Consultant Pediatric Dentist and Clinic Head at Clove Dental in Pune, I specialized in delivering comprehensive dental care, ranging from preventive treatments to surgical procedures and personalized care plans. My practice emphasized building trust with young patients and encouraging lifelong dental health habits, laying a strong foundation for healthy smiles well into the future.

CONTENT

❖ ANTERIOR AESTHETIC RESTORATION

- Strip Crown
- Omega loop & Strip Crown
- Fiber post & Strip Crown
- Composite restoration (Indirect putty method)
- Composite restoration (Direct method)

❖ SEMI PERMANENT RESTORATIONS

- Stainless Steel Crown
- Zirconia Crown

❖ FULL MOUTH REHABILITATION(FMR)

❖ SPACE MANTAINERS

- Short Band & Loop SM
- Crown Band & Loop SM
- Lingual Arch SM
- Nance palatal arch SM
- Distal Shoe SM

❖ INTERCEPTIVE ORTHODONTICS

- Quad Helix Appliance
- Correction Anterior Crossbite
 - a) Ice cream stick
 - b) Jackson Expansion screw
 - c) Double Cantilever Spring

❖ HABIT BREAKING APPLIANCES

- Tongue thrusting
- Thumb Sucking
- Bruxism
- Lip Biting Habit

❖ FRAGMENT RE-ATTACHEMENT

CONTENT

❖ PEDIATRIC PROSTHODONTICS

- RPD wrt 11
- RPD wrt 36
- RPD wrt 14,24,25
- Zirconia 11
- Fiber Post & Zirconia Crown 22
- Acrylic crown 21
- Porcelain Fused Metal (PFM)

❖ REGENERATIVE ENDODONTICS

- Apexogenesis using PRF
- Vertical bone loss using PRF
- MTA Apexification
- Biodentine Apexification

❖ MINOR ORAL SURGICAL PROCEDURE

- Mesiodens
- Natal & Neo-Natal tooth
- Mucocele excision
- Pericoronal Flap Excision
- Tongue Laceration
- Radicular Cyst

❖ LASER SURGICAL PROCEDURES

- Laser Mucocele Excision
- Laser Fibroma Excision
- Laser Lingual Frenectomy
- Laser Labial Frenectomy

❖ PREVENTIVE DENTISTRY

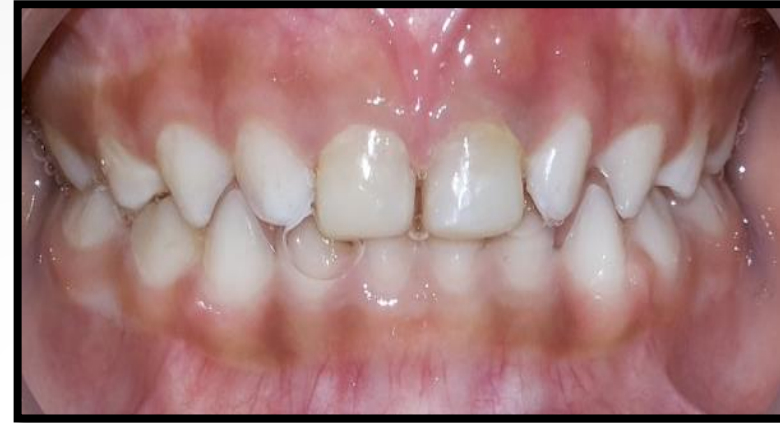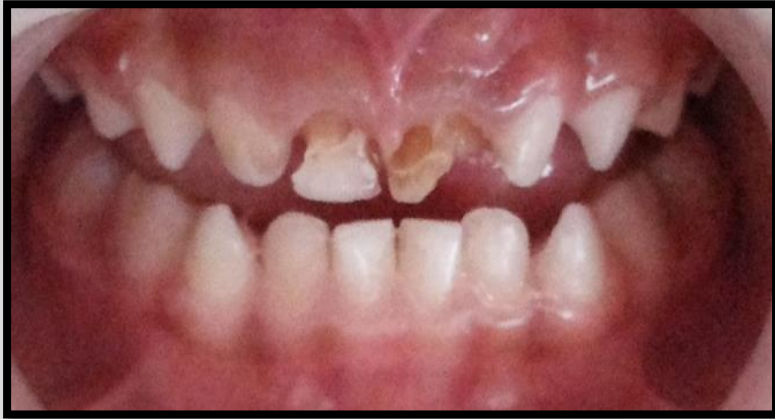- Pit & Fissure Sealants
- Preventive Resin Restoration
- Topical Fluoride application
- Resin Infiltration

❖ PULP THERAPY

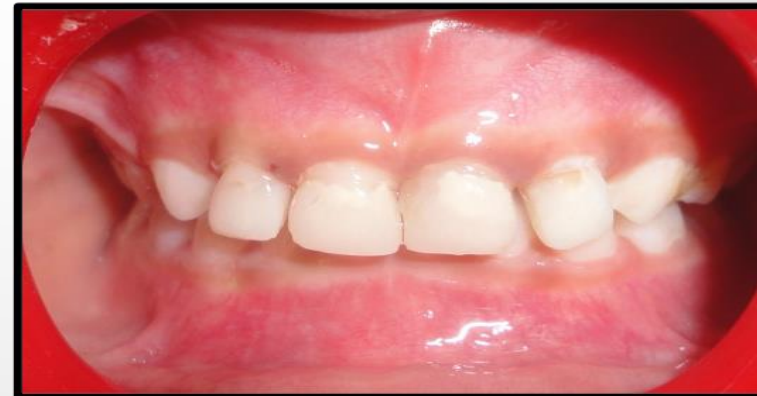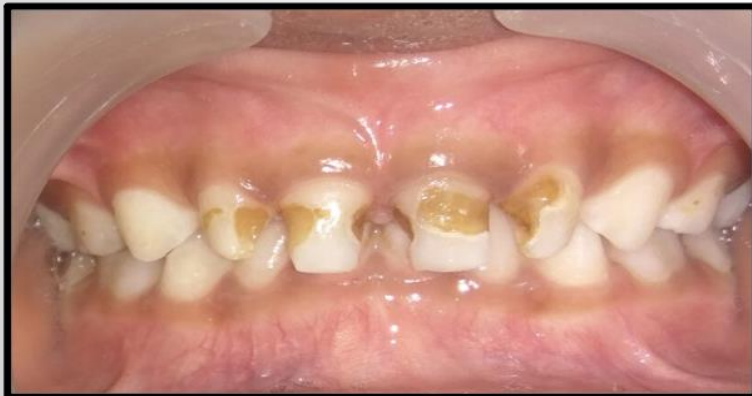❖ ALBIFICATIONS: VITAL & NON-VITAL

ANTERIOR AESTHETIC RESTORATION

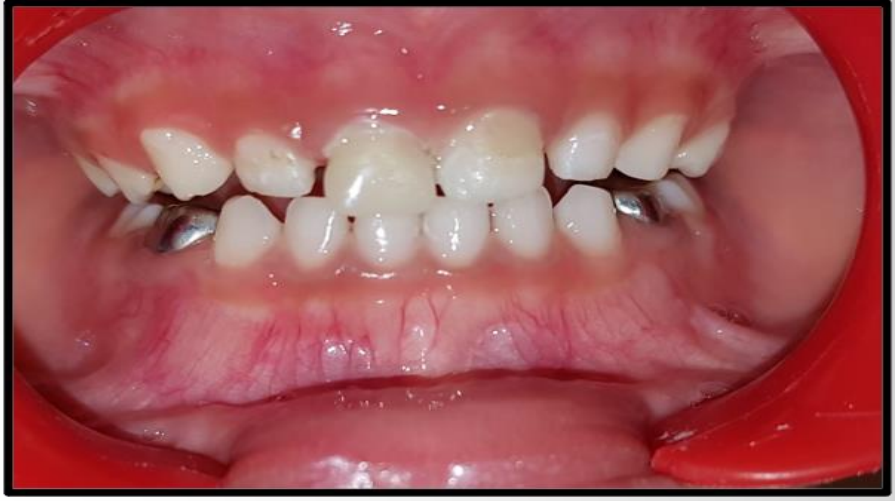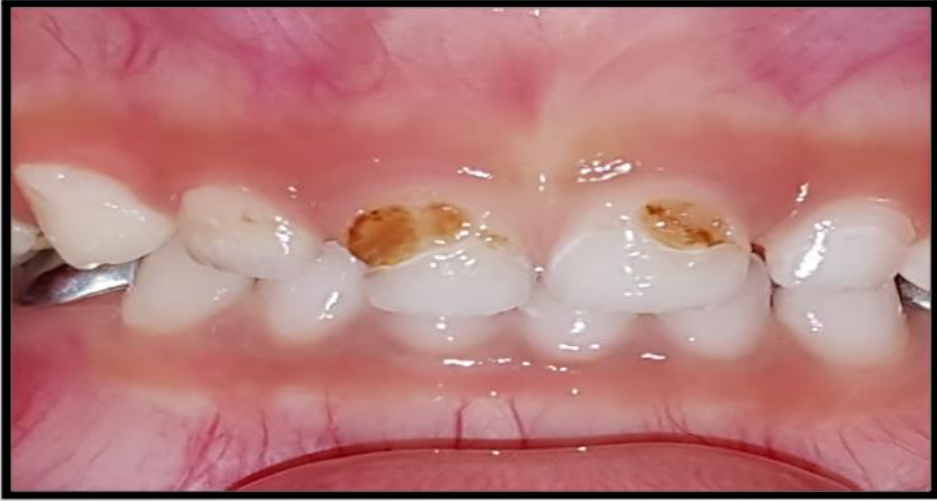RESTORATION OF PRIMARY TEETH WITH STRIP CROWN



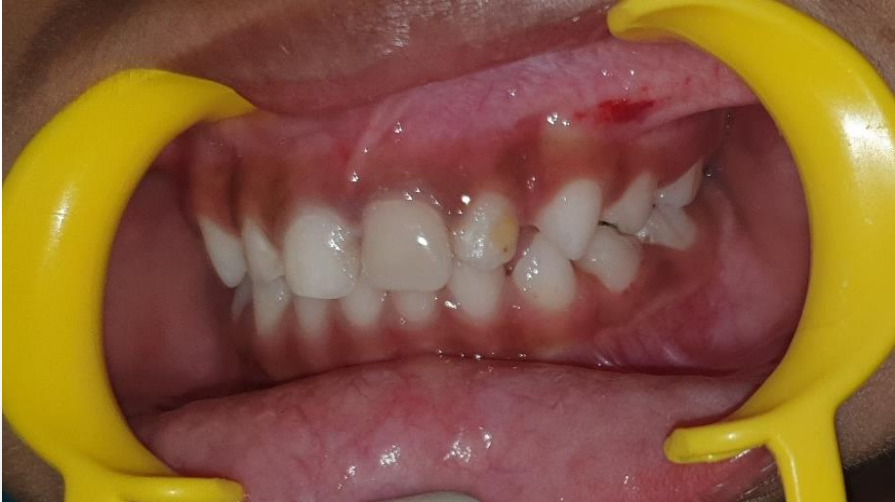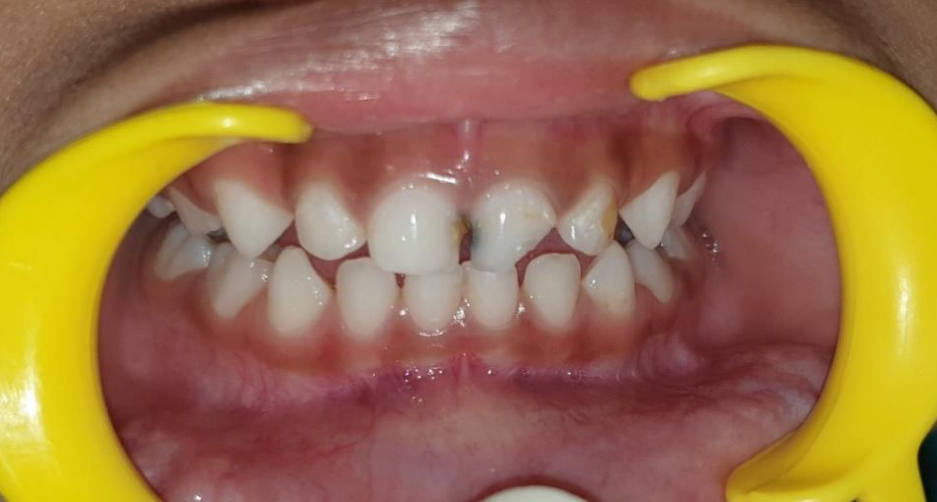CASE 1



CASE 2

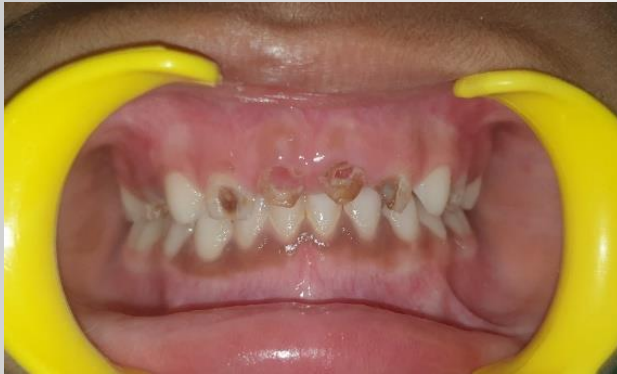

CASE 3

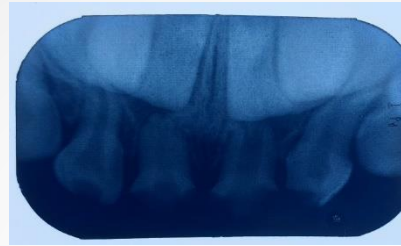


CASE 4

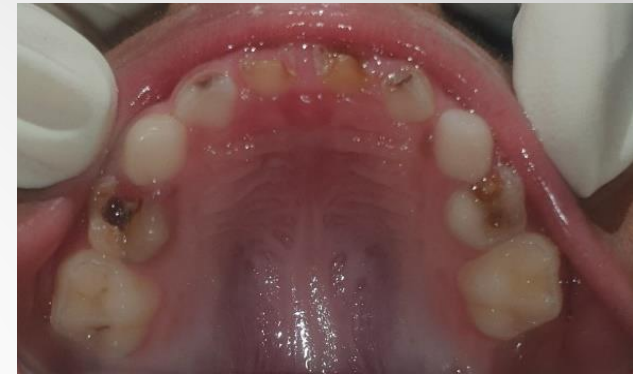RESTORATION OF PRIMARY TEETH WITH OMEGA LOOP AND STRIP CROWN



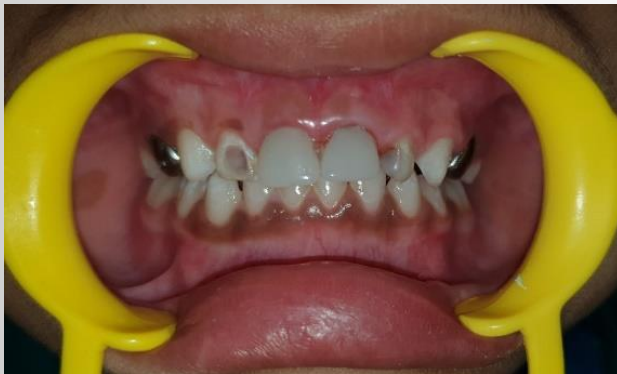PRE OP FRONTAL



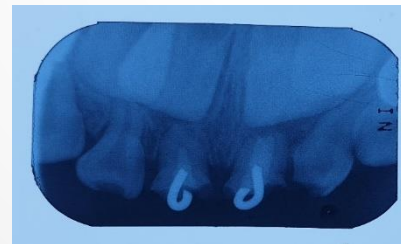
PRE OP RADIOGRAPH



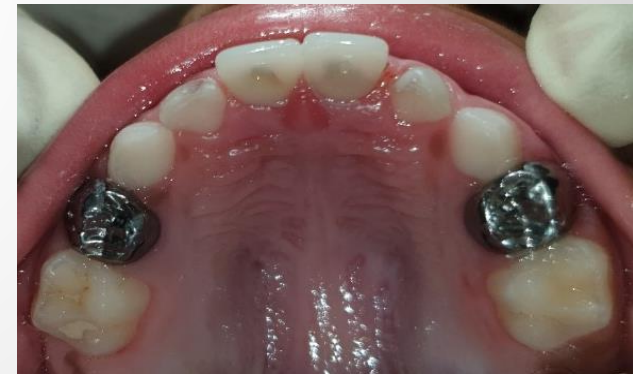PRE OP OCCLUSAL



POST OP FRONTAL

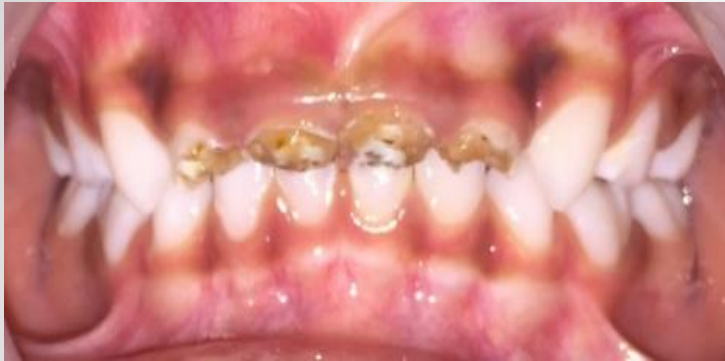

OMEGA LOOP POST PLACED W.R.T
51, 61

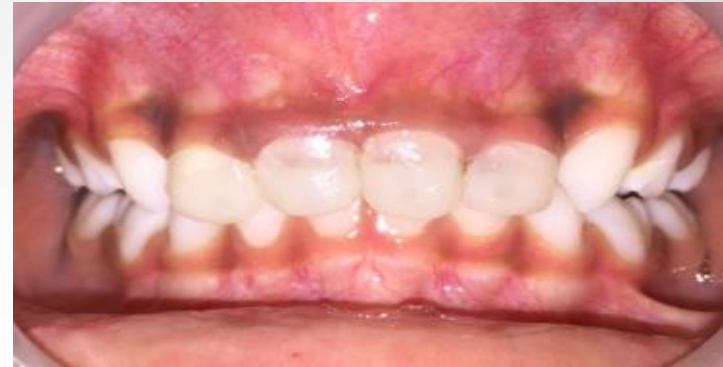

POST OP OCCLUSAL

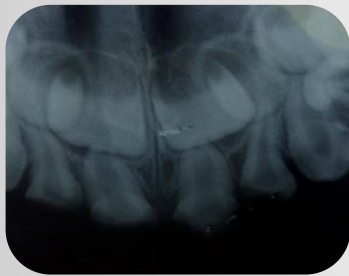**Post and core in relation to grossly carious primary anterior teeth using
Fiber post**



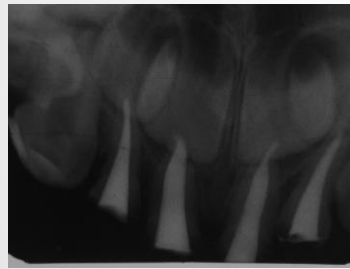Pre op frontal view



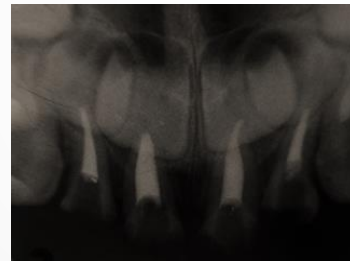
Post op frontal view



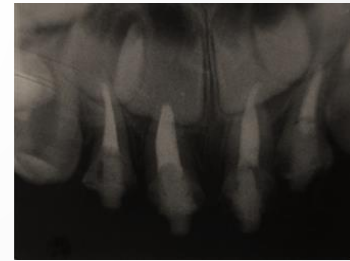
Pre op IOPA: 51,52,61,62



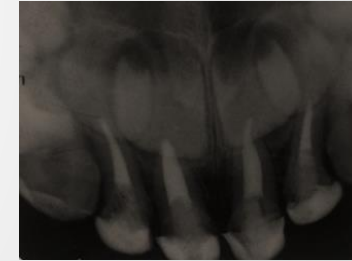
**Post op IOPA –
pulpectomy**



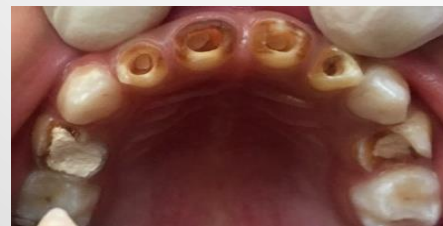**Post op IOPA –
post space**



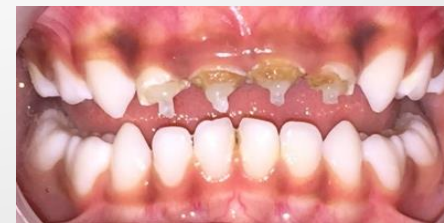Post op IOPA



Post op IOPA – Post cementation

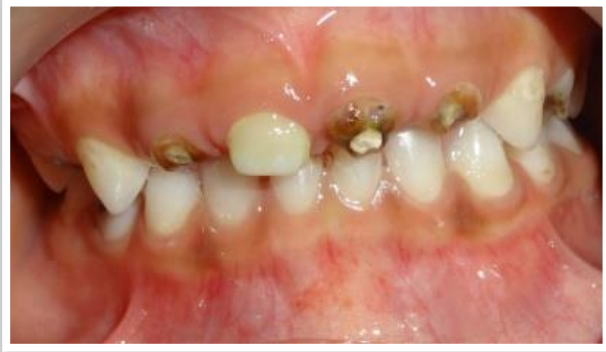

Post op occlusal view– post space

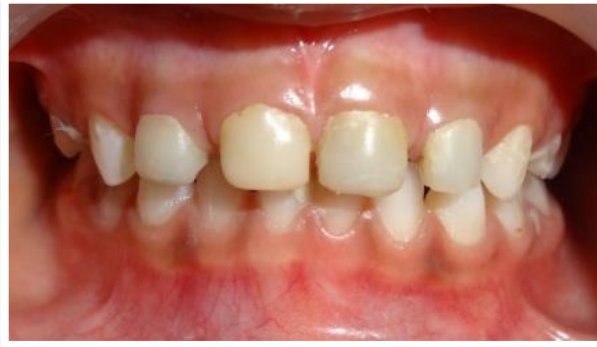

Post Fiberpost

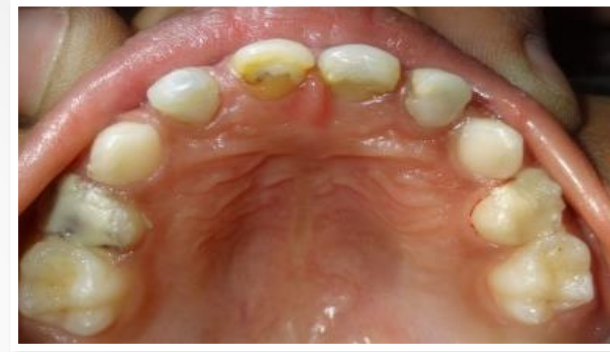Anterior Composite build up using Omega Loops in relation to 61,62,52



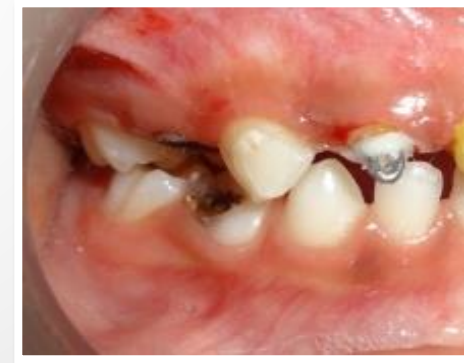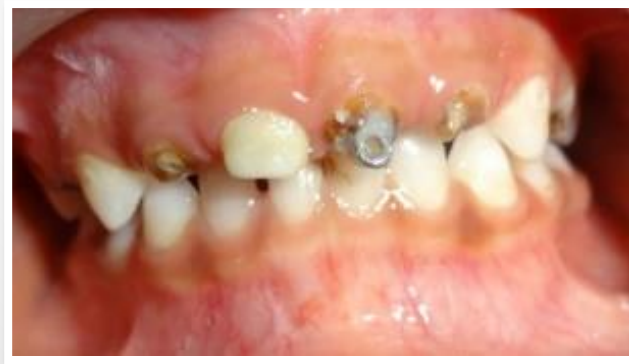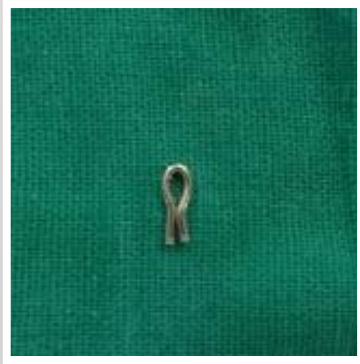Pre op



Post op – frontal view

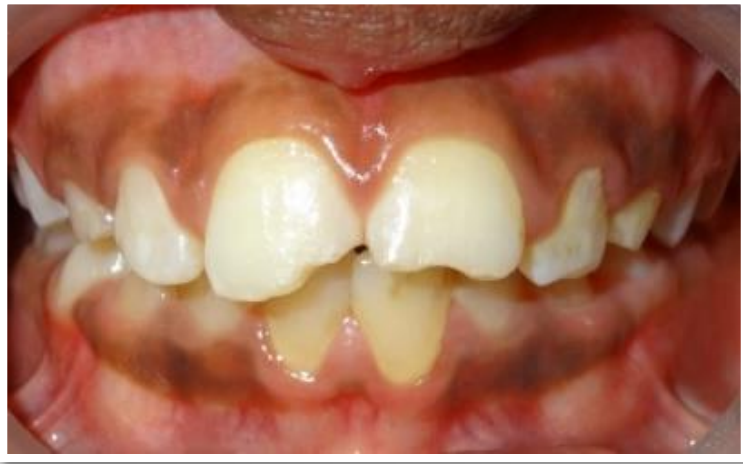

Post op – occlusal view

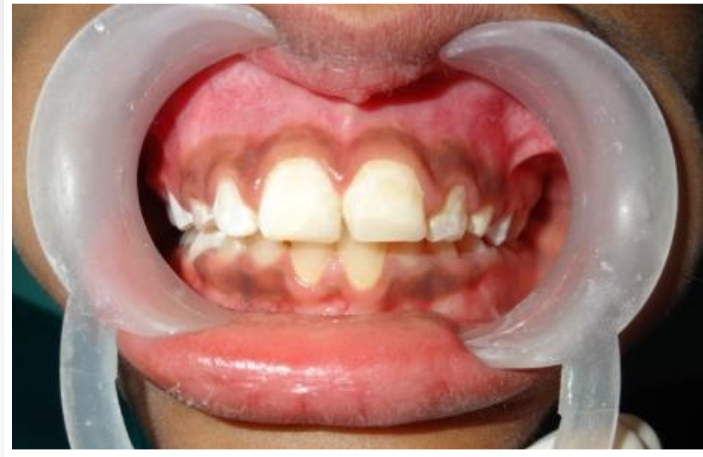

Placement of omega loop

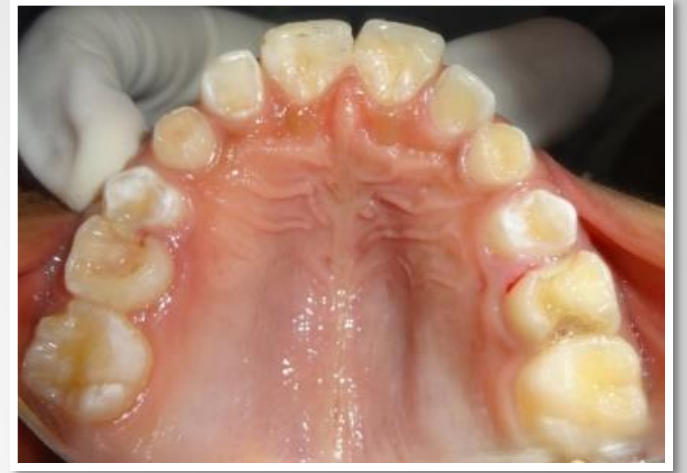COMPOSITE RESOTRATION i.r.t 11, 21 USING PUTTY TRMPLATE



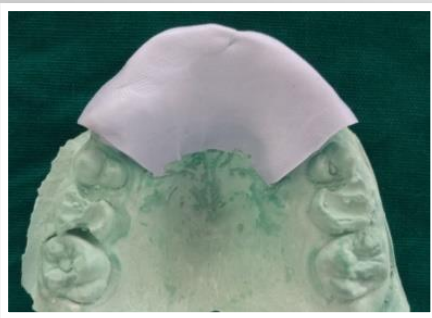Pre op



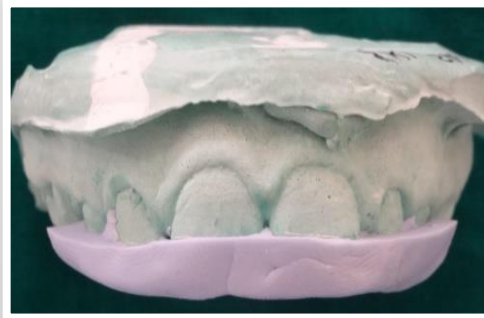Post op – frontal view



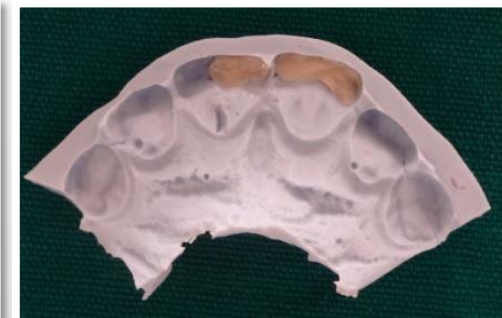
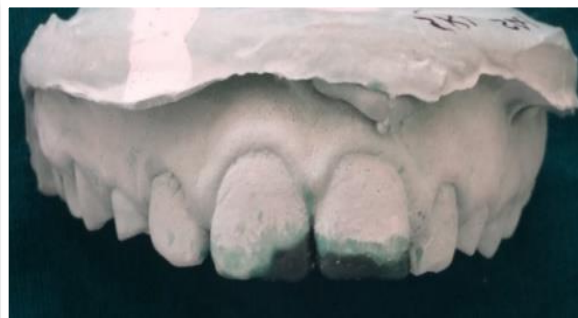Post op – Occlusal view



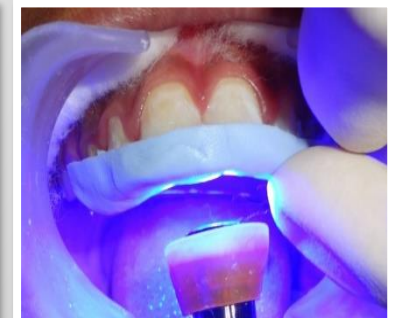Fabrication of putty template



Wax build up of 11, 21

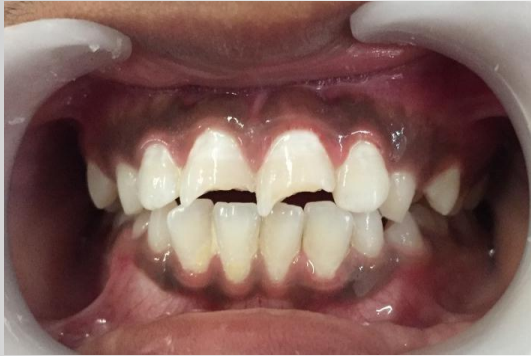

Loading of composite
in template

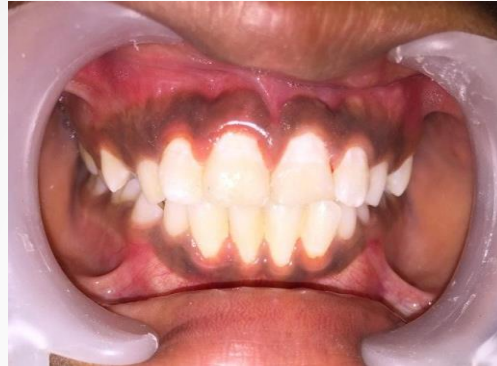

Light curing

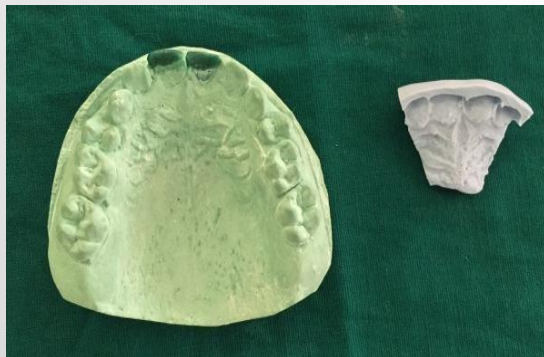ANTERIOR DIRECT COMPOSITE RESTORATION IN RELATION TO 11,21



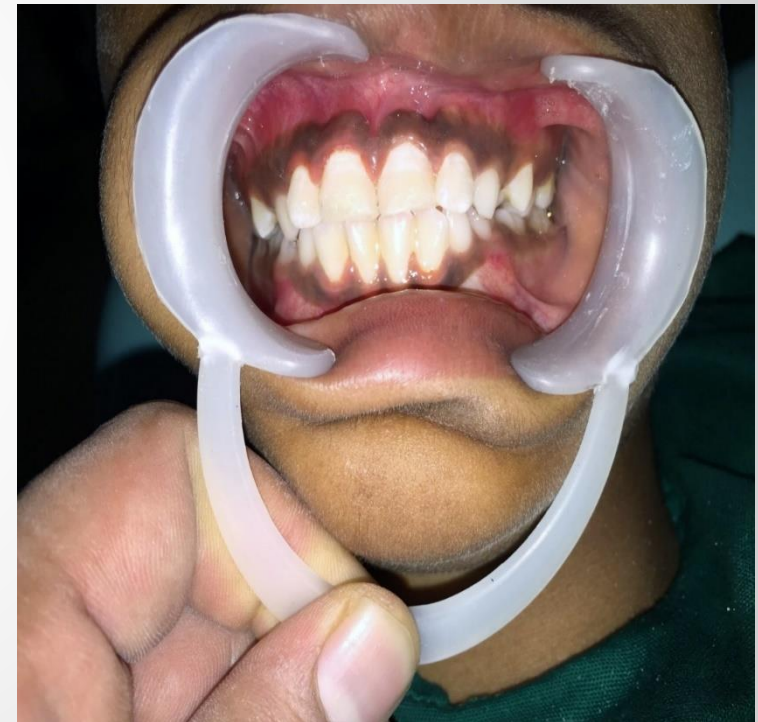PRE OP FRONTAL VIEW



POST OP FRONTAL VIEW

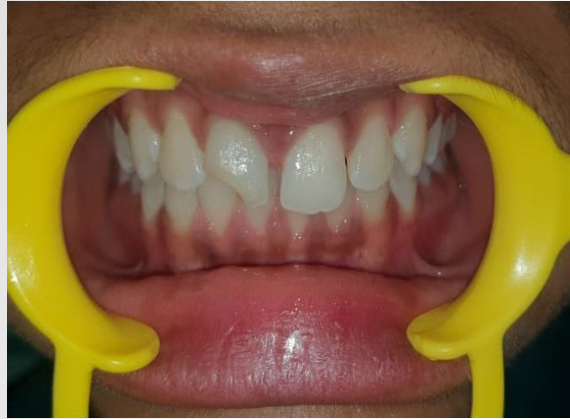

Fabrication of putty template

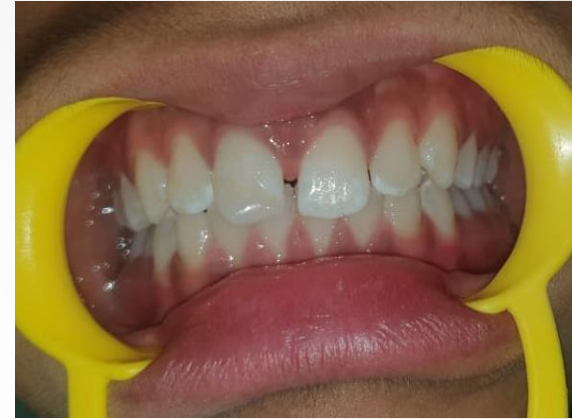

POST OP FRONTAL VIEW

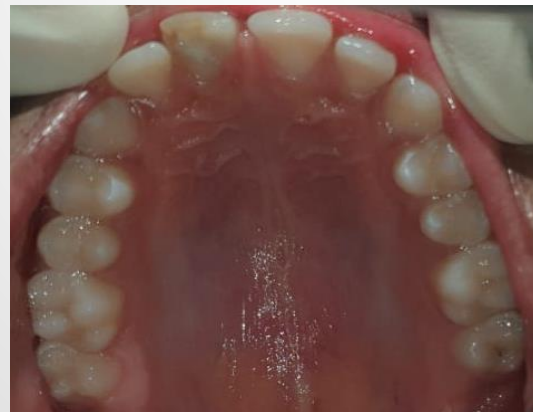ANTERIOR DIRECT COMPOSITE RESTORATION IN RELATION TO 11



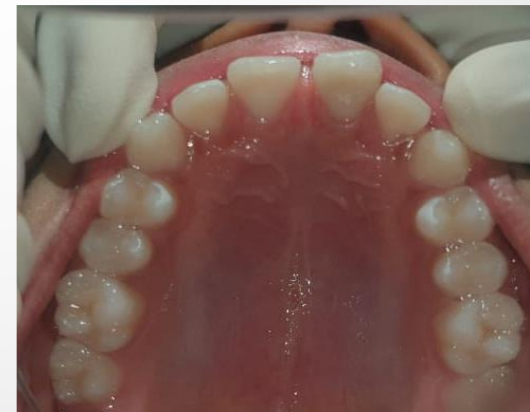PRE OP FRONTAL VIEW



POST OP FRONTAL VIEW



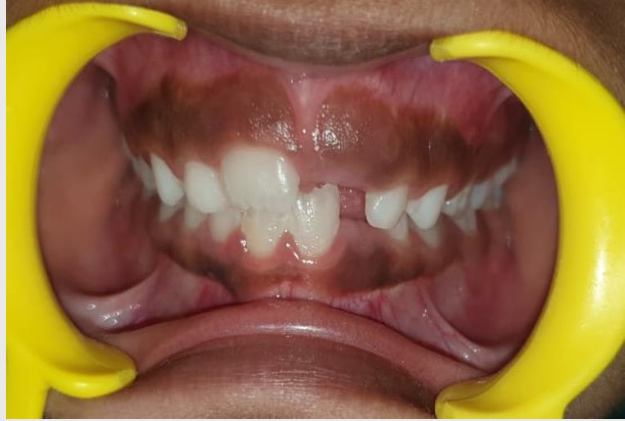PRE OP OCCLUSAL VIEW



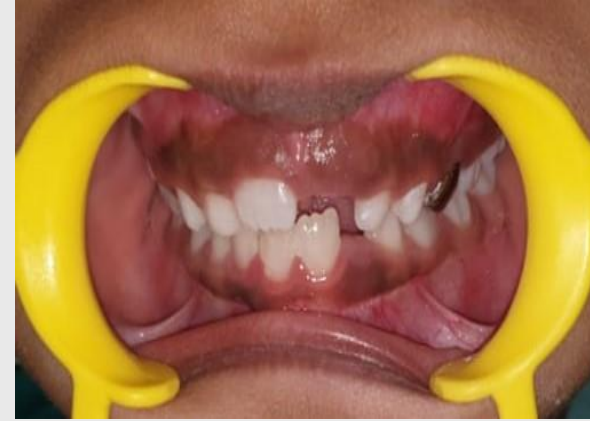POST OP OCCLUSAL VIEW

SEMI PERMANENT
RESTORATIONS

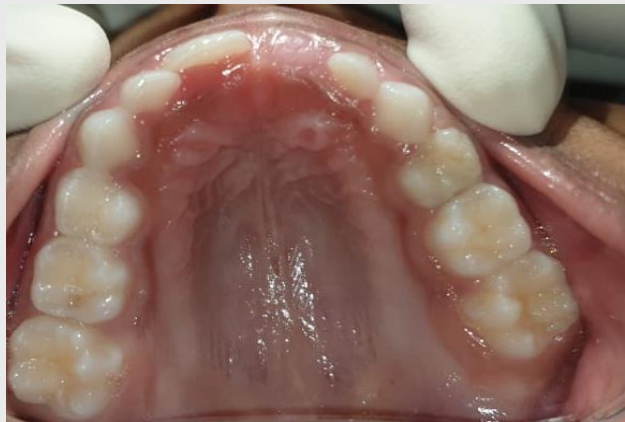STAINLESS-STEEL MAXILLARY STAINLESS-STEEL CROWN



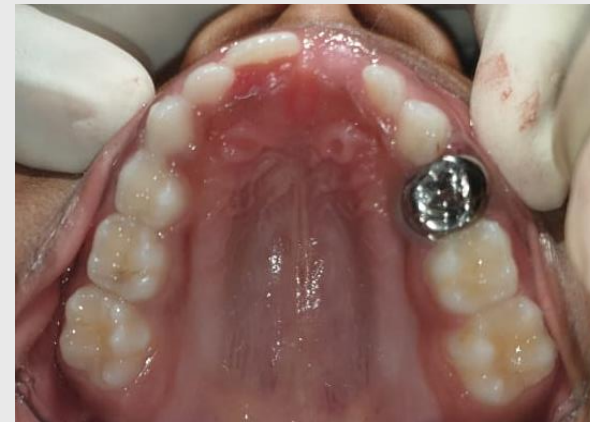PRE OP FRONTAL



POST OP FRONTAL

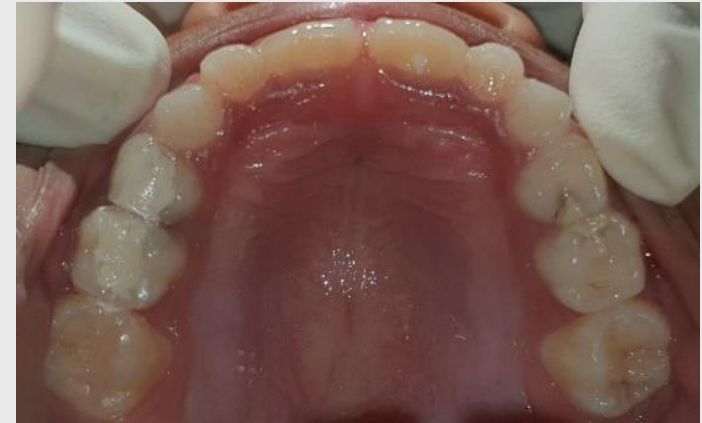
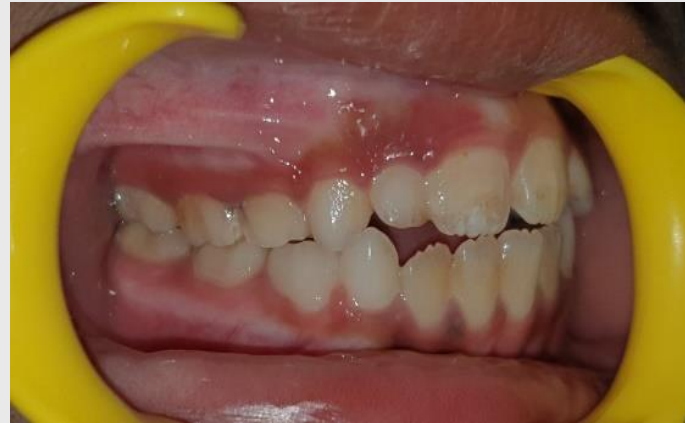
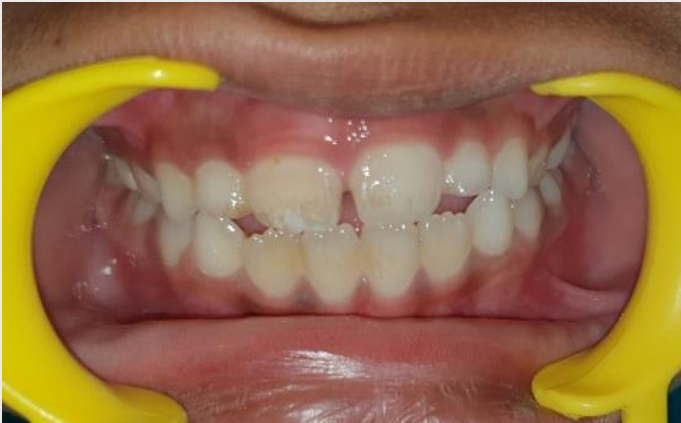PRE OP OCCLUSAL

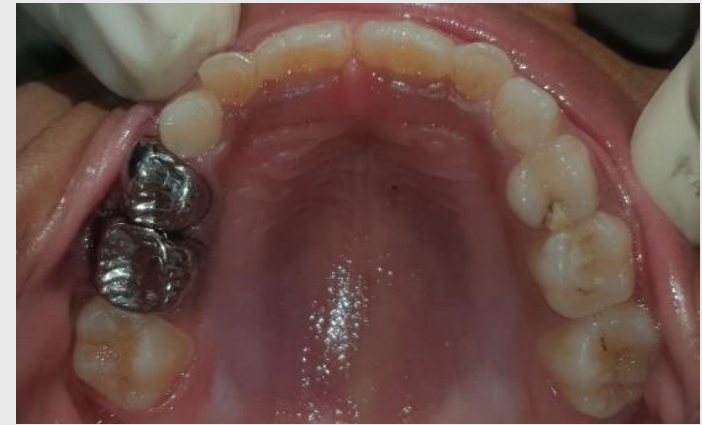
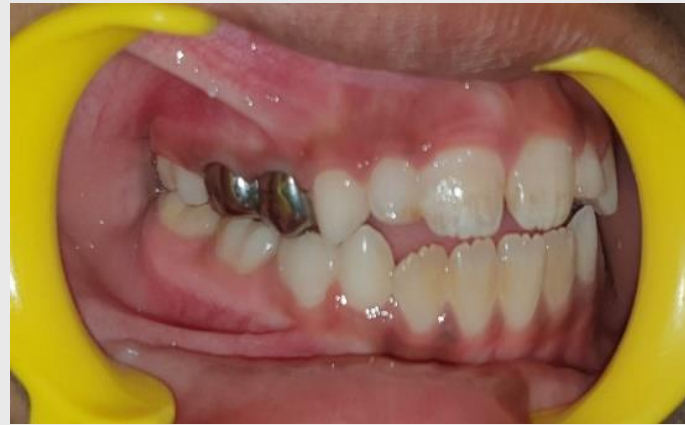
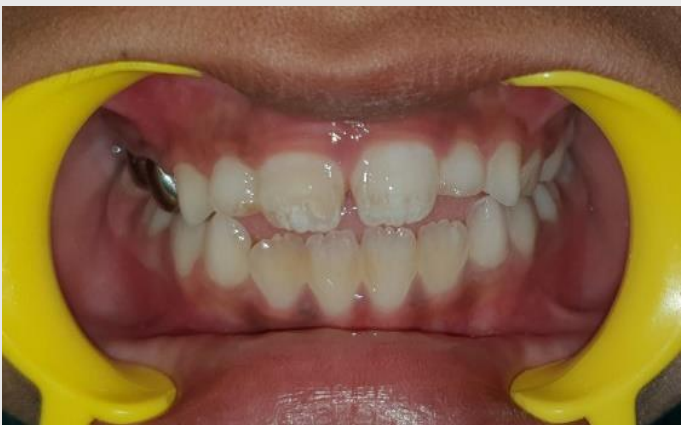POST OP OCCLUSAL

ADJACENT MAXILLARY STAINLESS-STEEL CROWN

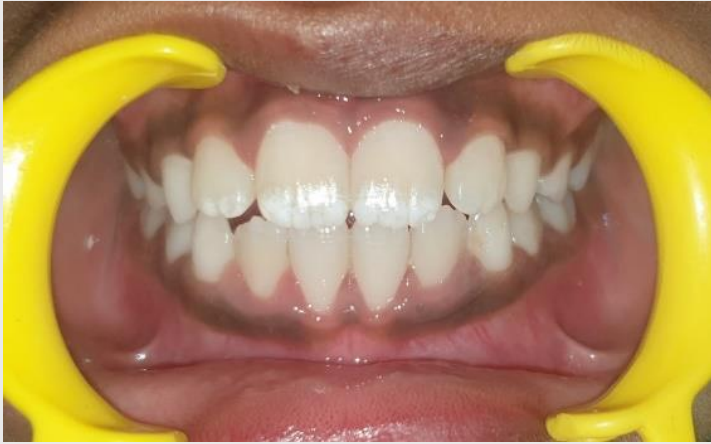

PRE OP VIEW

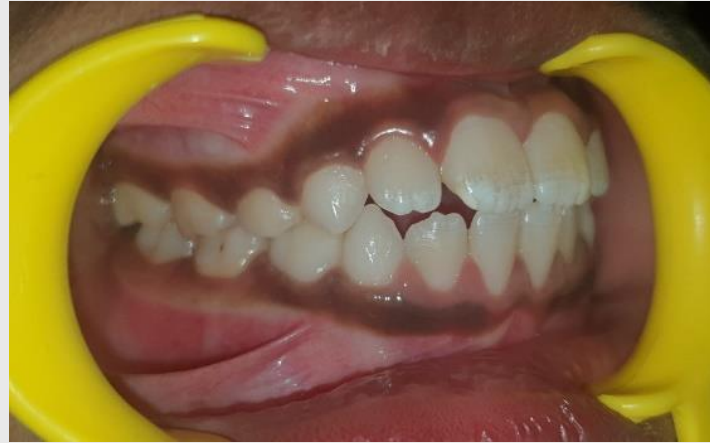

POST OP VIEW

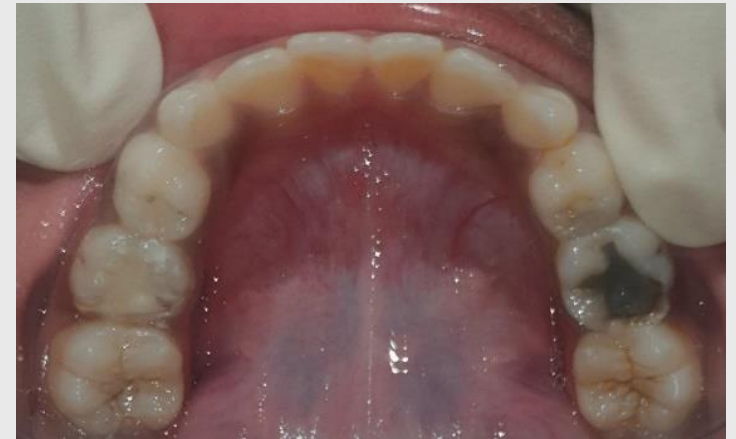**UNILATERAL MANDIBULAR STAINLESS-STEEL
CROWN**



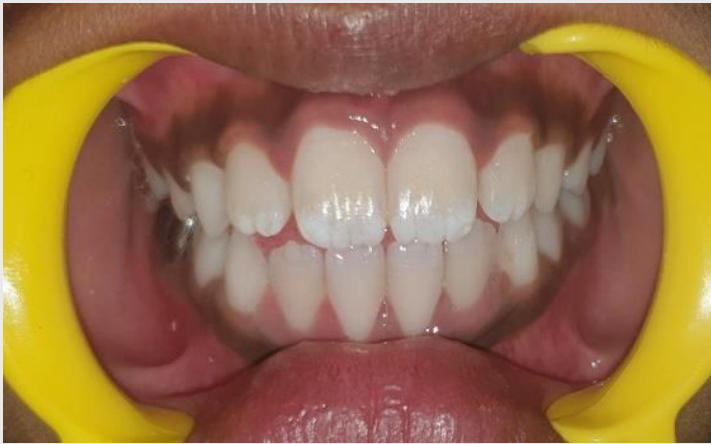PRE OP FRONTAL



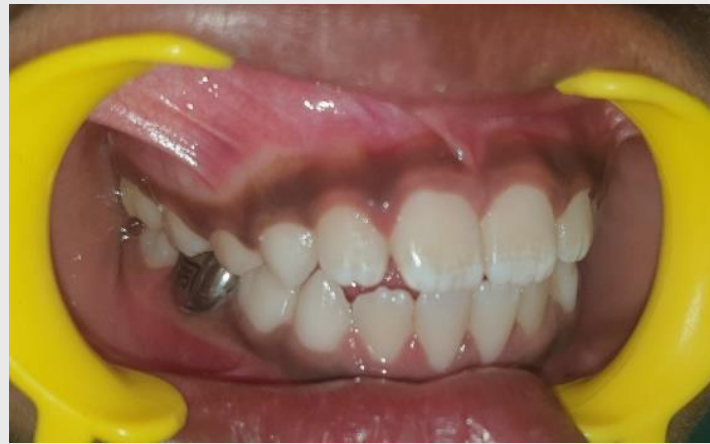PRE OP RIGHT LATERAL VIEW



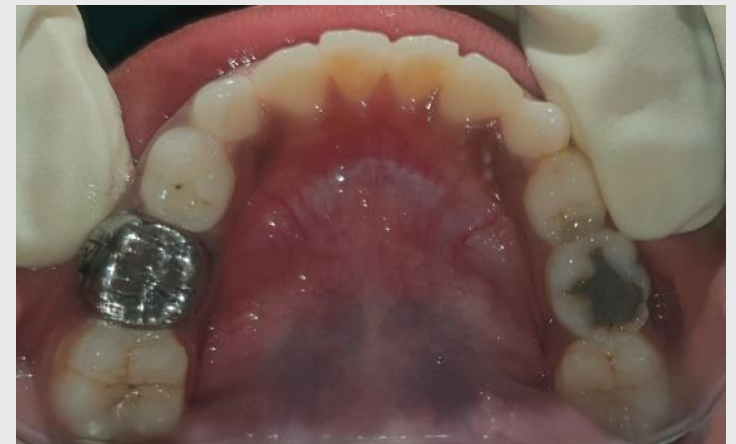PRE OP OCCLUSAL



POST OP FRONTAL

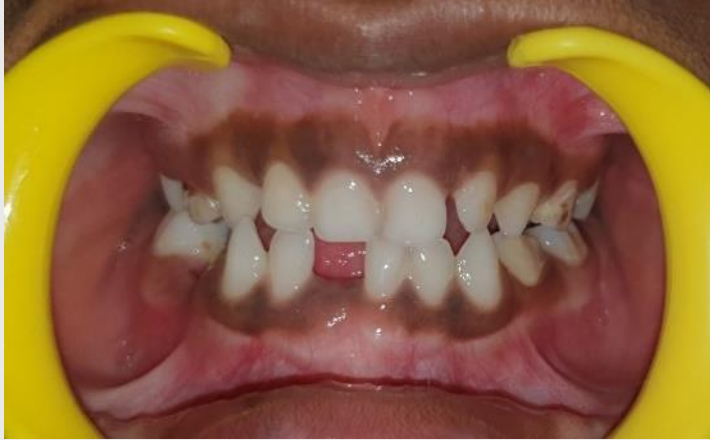

POST OP RIGHT LATERAL VIEW

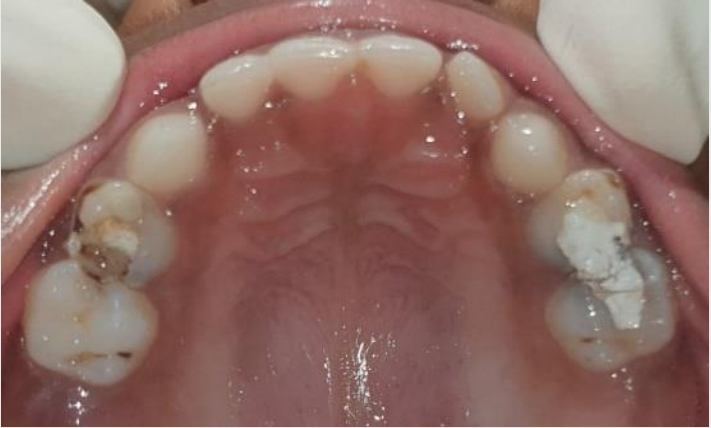

POST OP OCCLUSAL

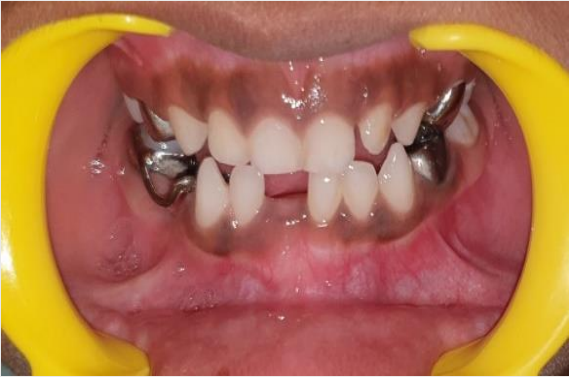**BILATERAL MAXILLARY STAINLESS-STEEL
CROWN**



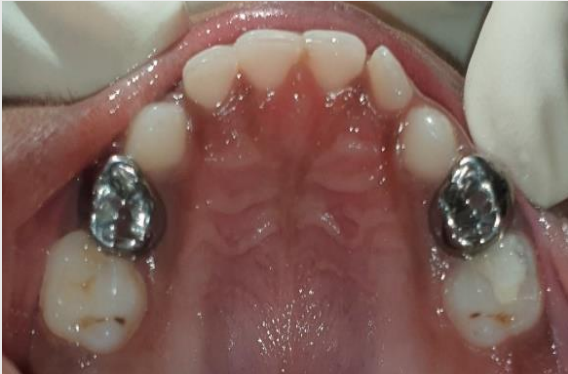PRE OP FRONTAL



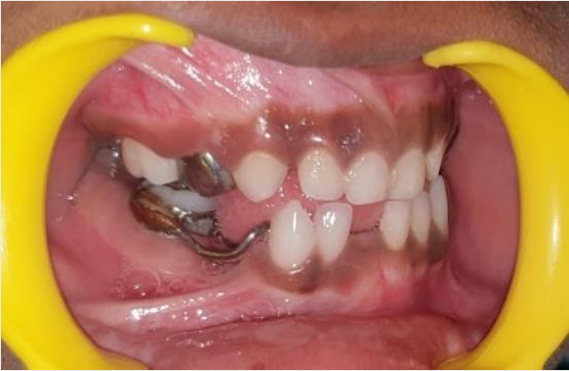PRE OP OCCLUSAL



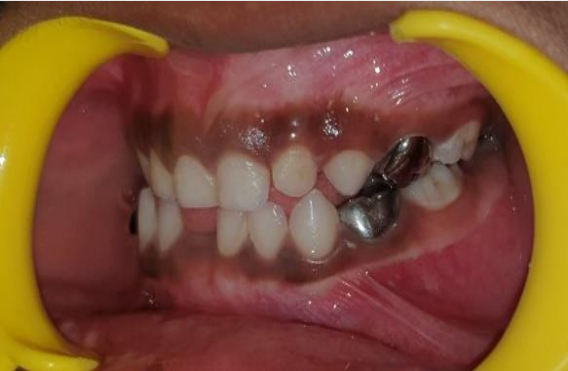POST OP FRONTAL



POST OP OCCLUSAL

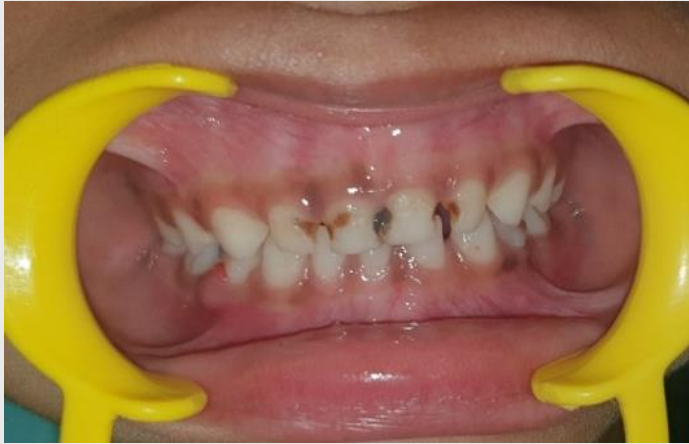

POST OP RIGHT LATERAL VIEW

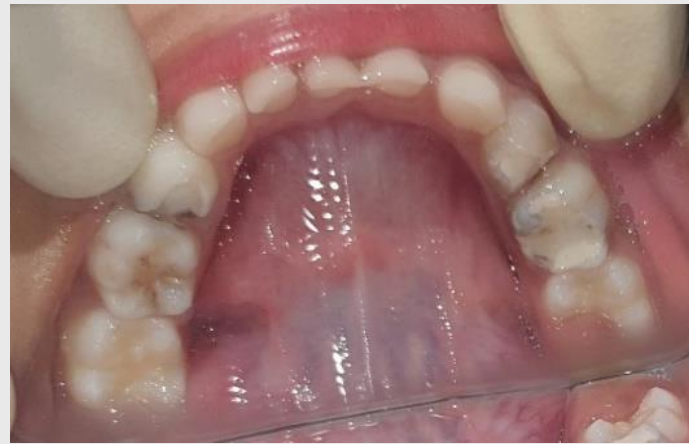

POST OP LEFT LATERAL VIEW

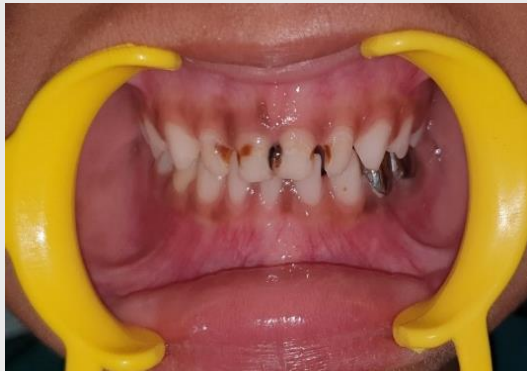BILATERAL & ADJACENT MANDIBULAR STAINLESS-STEEL CROWN



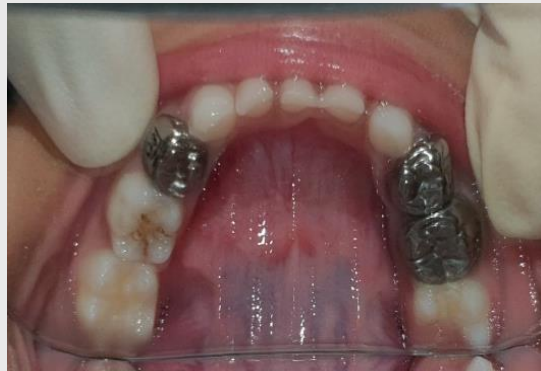PRE OP FRONTAL



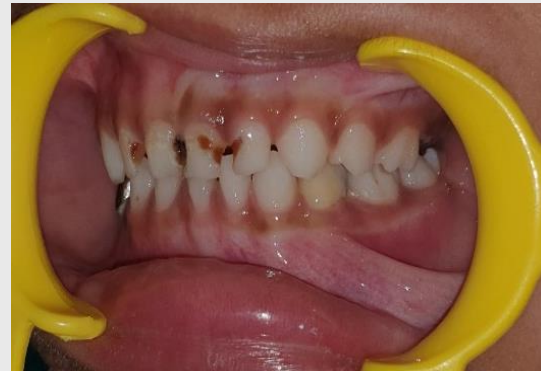PRE OP OCCLUSAL



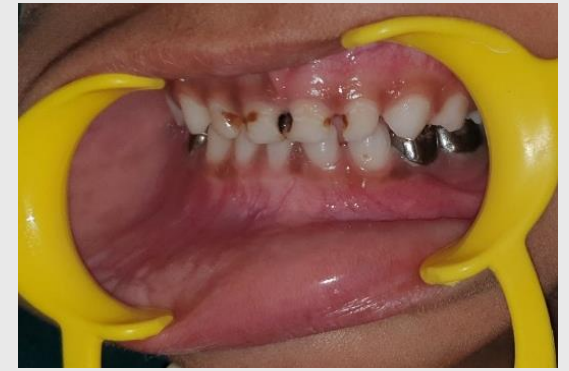POST OP FRONTAL



POST OP OCCLUSAL

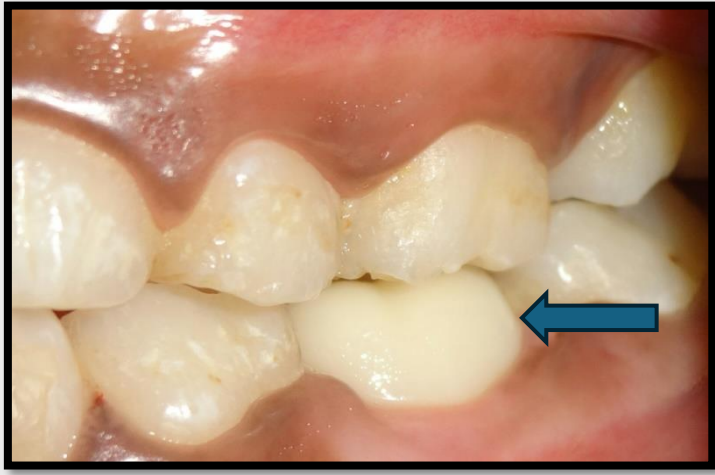
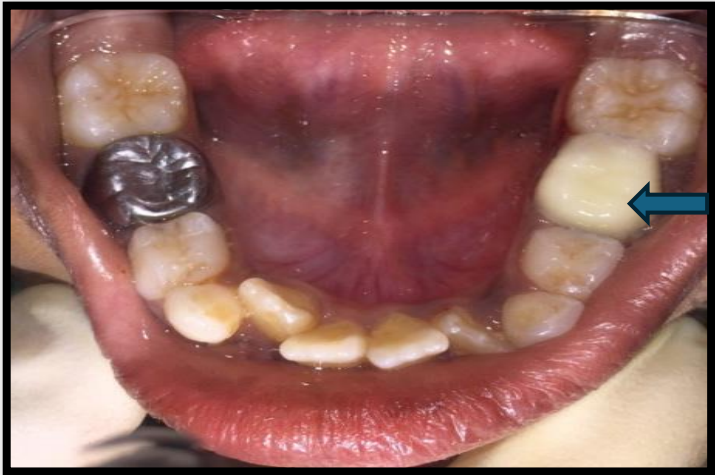
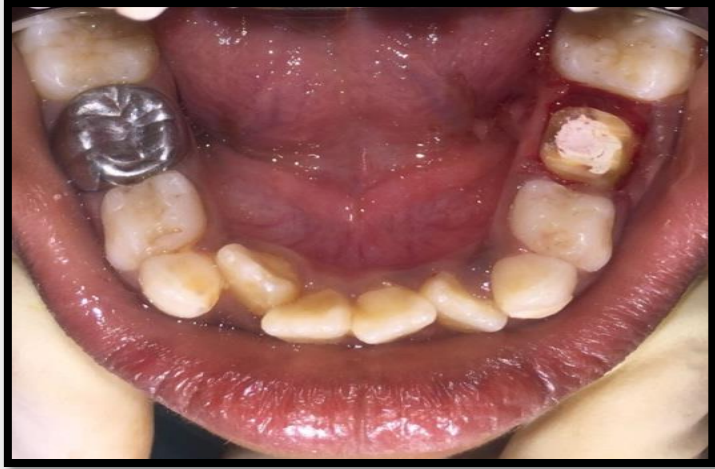
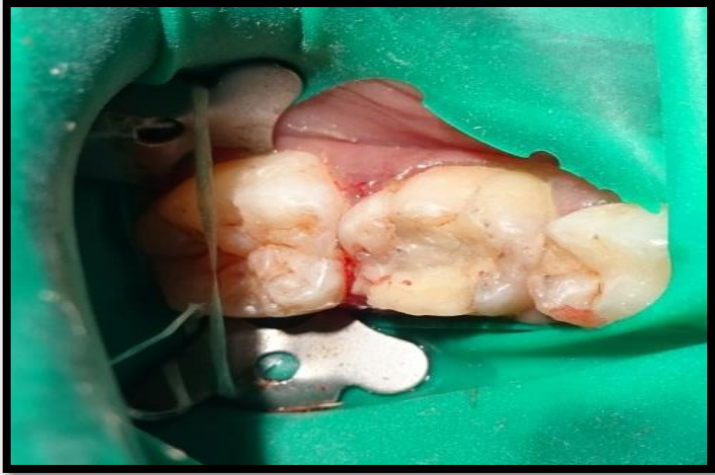POST OP RIGHT LATERAL VIEW

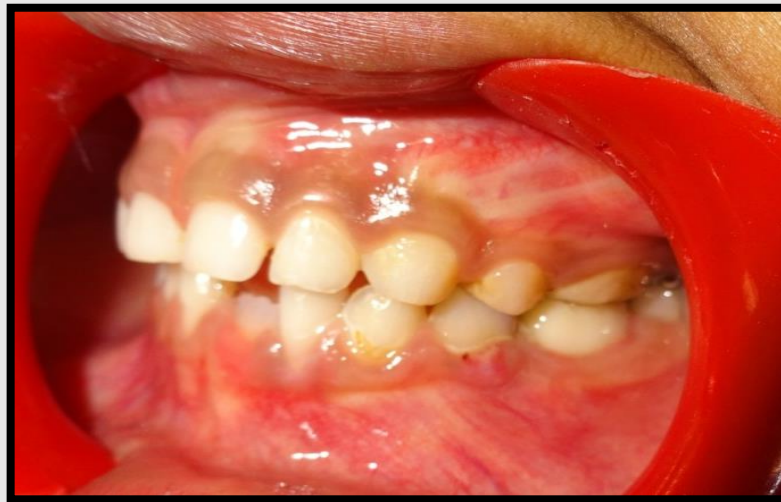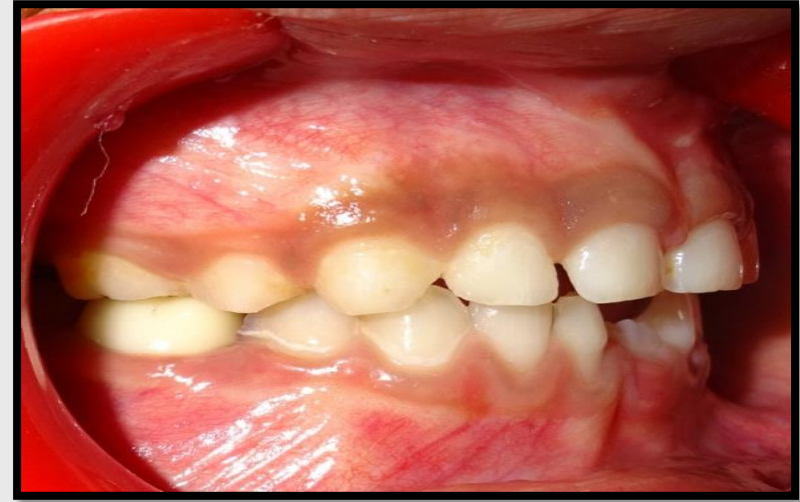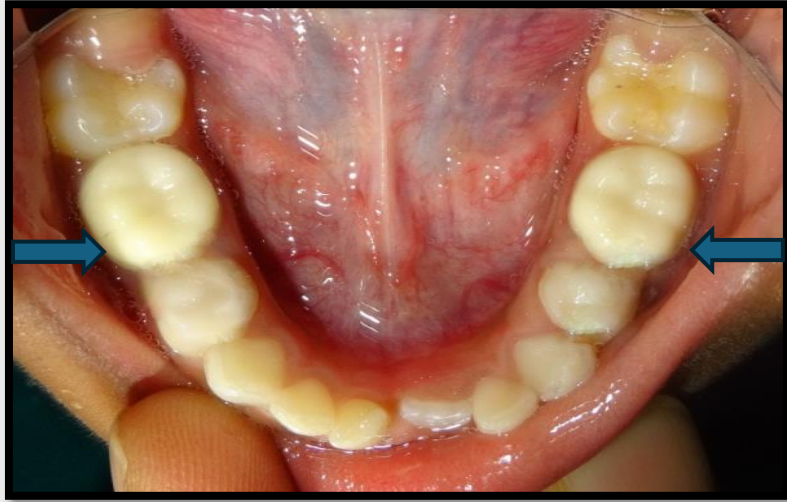


POST OP LEFT LATERAL VIEW

Zirconia CROWN

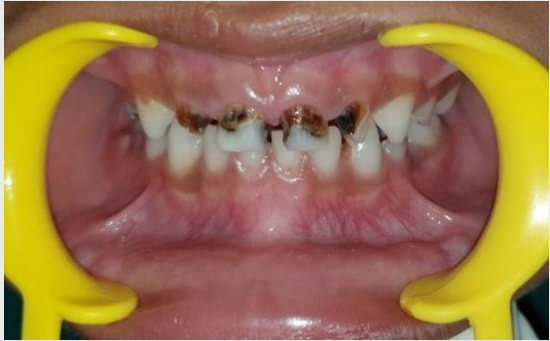

Preformed Zirconia crown

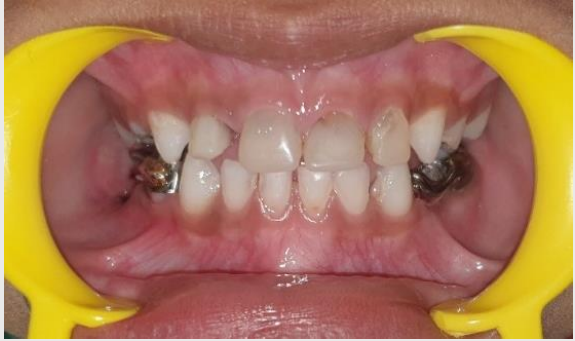

COMPLETE ORAL REHABILITATION

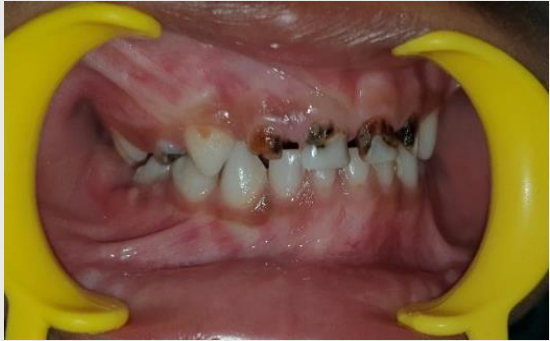MANAGEMENT OF EARLY CHILDHOOD CARIES



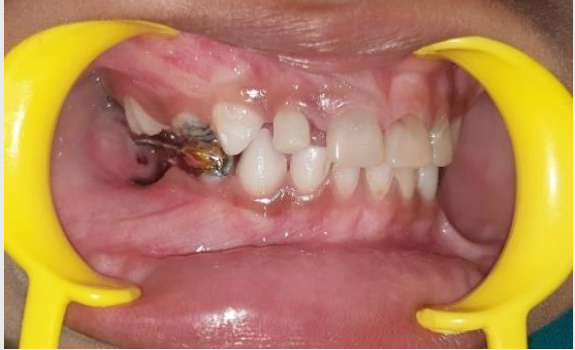PRE OP FRONTAL VIEW



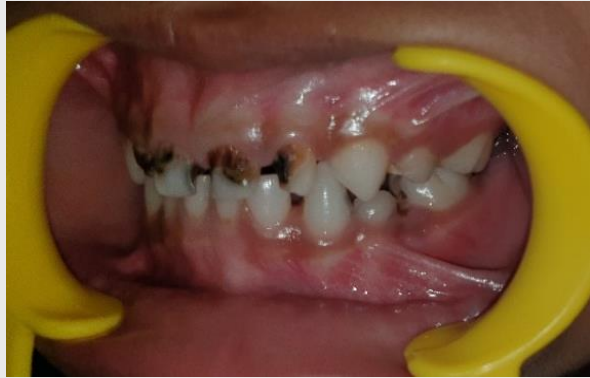POST OP FRONTAL VIEW



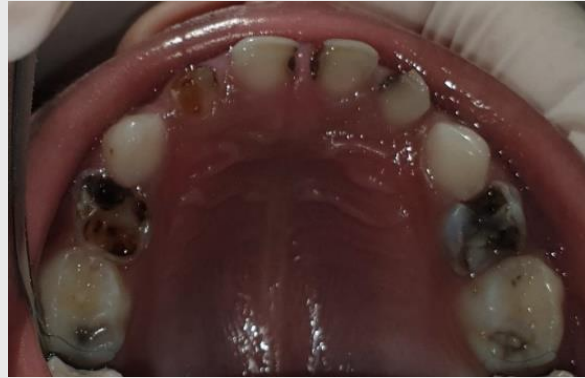PRE OP RIGHT OCCLUSION



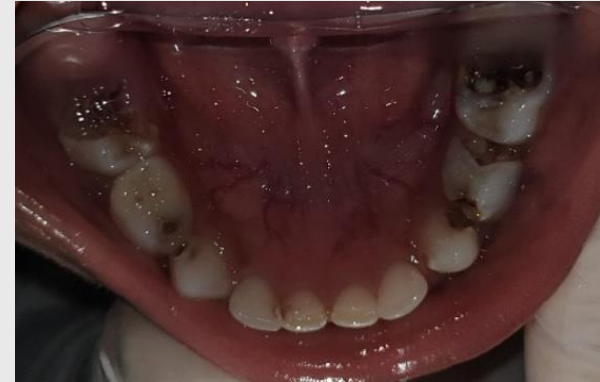POST OP RIGHT OCCLUSION



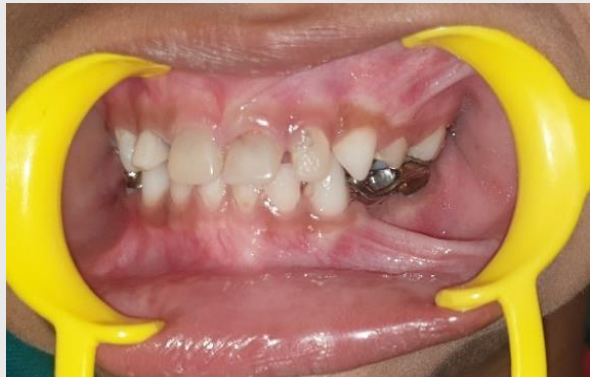PRE OP OCCLUSION



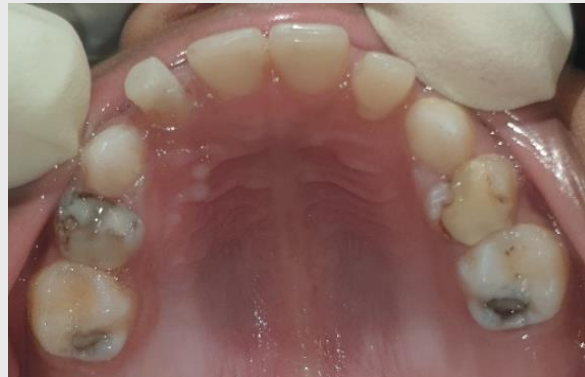PRE OP MAXILLARY VIEW



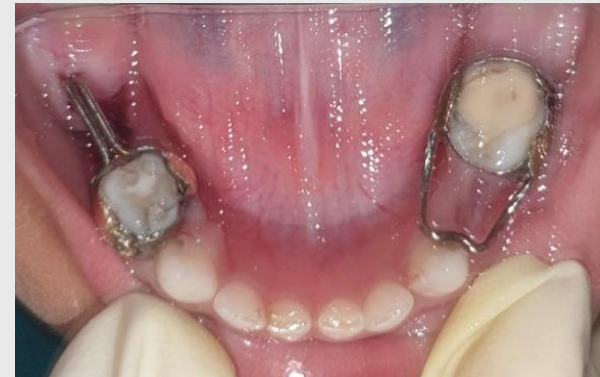PRE OP MANDIBULAR VIEW



POST OP OCCLUSION



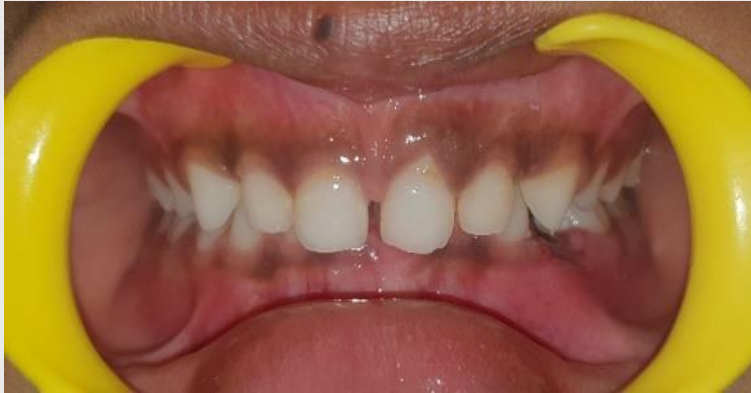POST OP MAXILLARY VIEW



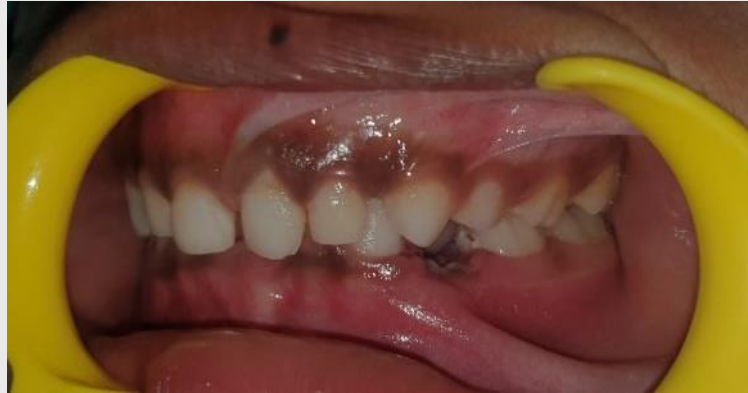POST OP MANDIBULAR VIEW

SPACE MANAGEMENT

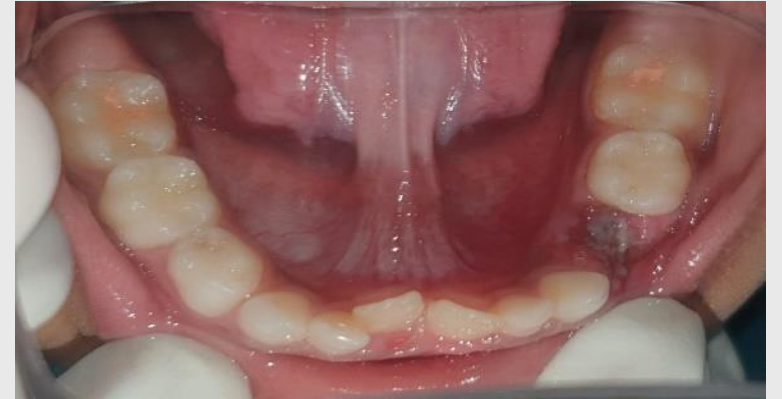SHORT BAND AND LOOP SPACE MAINTAINER



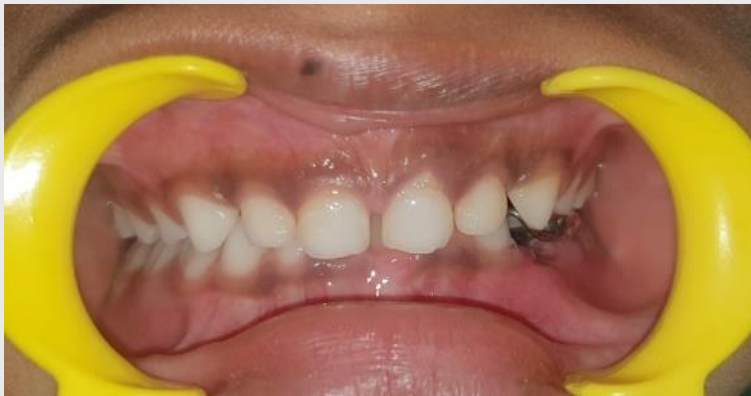PRE OP FRONTAL VIEW



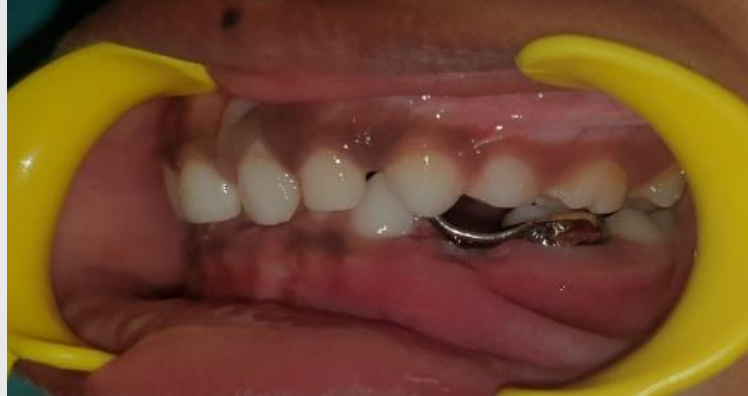PRE OP LATERAL VIEW



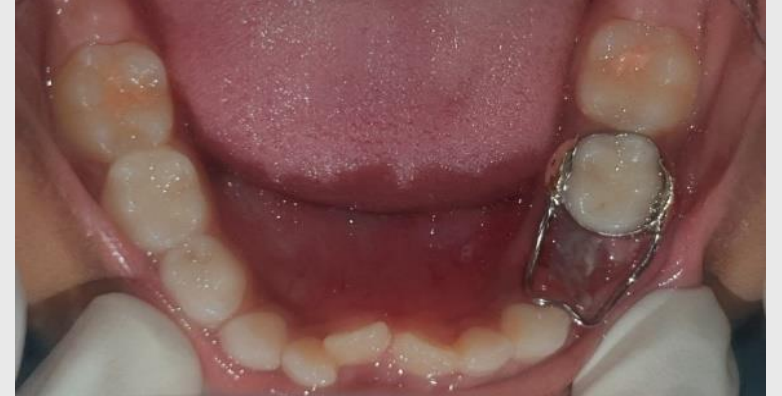PRE OP OCCLUSAL VIEW



POST OP FRONTAL VIEW

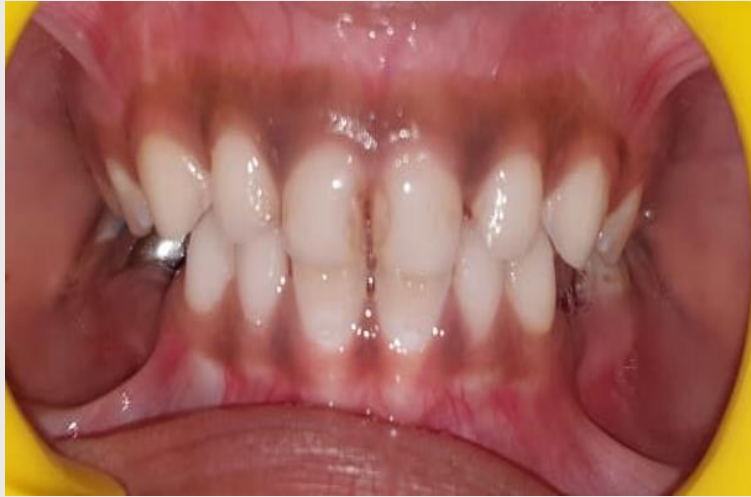

POST OP LATERAL VIEW

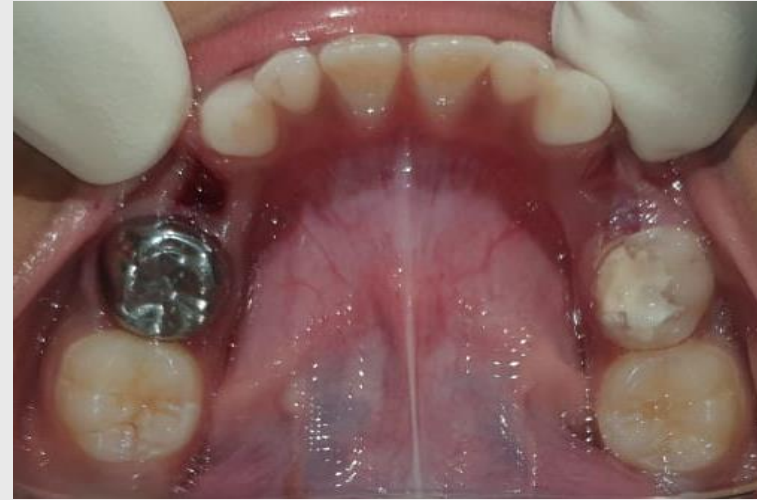

POST OP OCCLUSAL VIEW

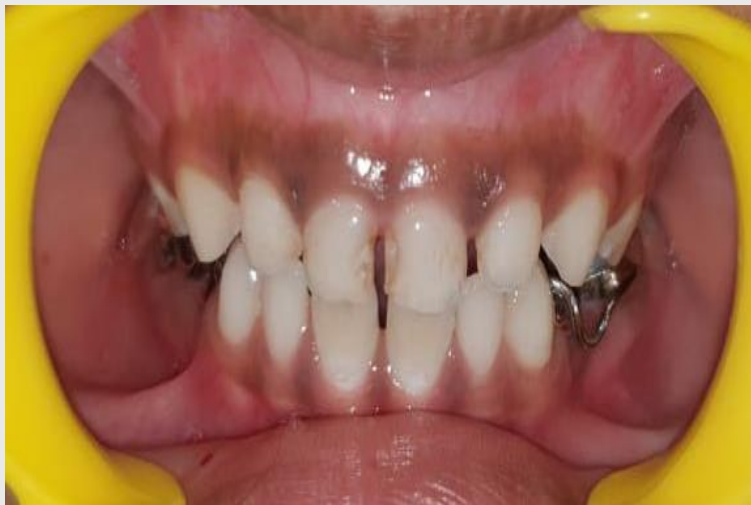CROWN BAND AND LOOP SPACE MAINTAINER



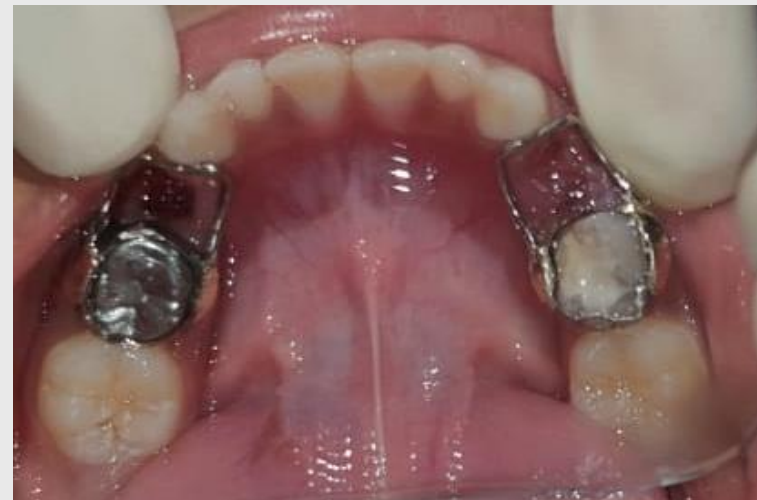PRE OP FRONTAL VIEW



PRE OP OCCLUSAL VIEW

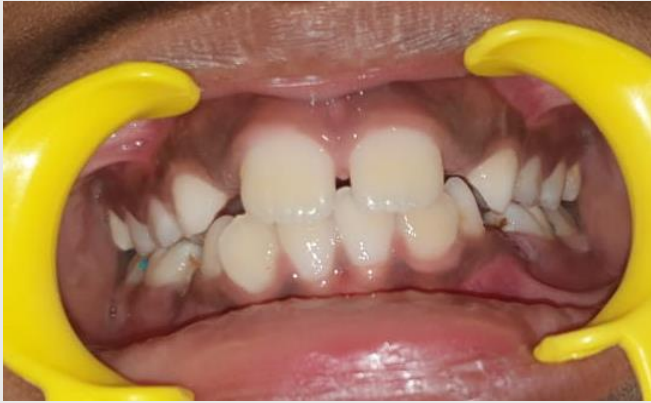

POST OP FRONTAL VIEW

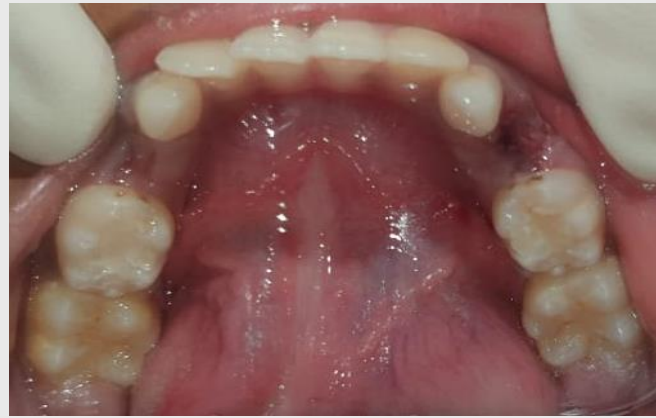

POST OP OCCLUSAL VIEW

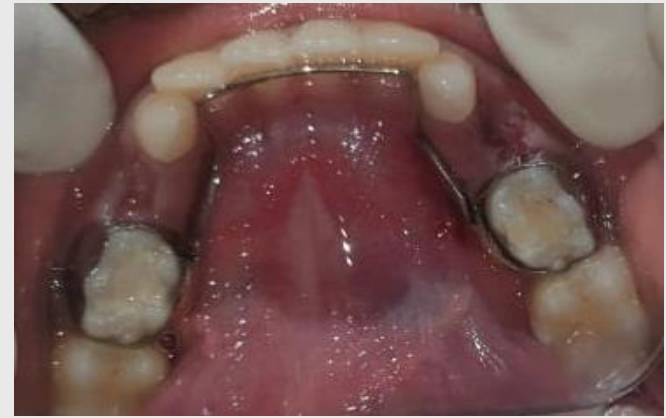LINGUAL ARCH SPACE MAINTAINER



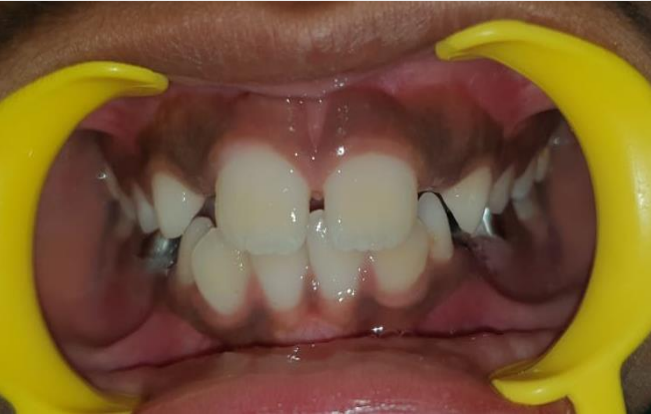PRE OP FRONTALVIEW



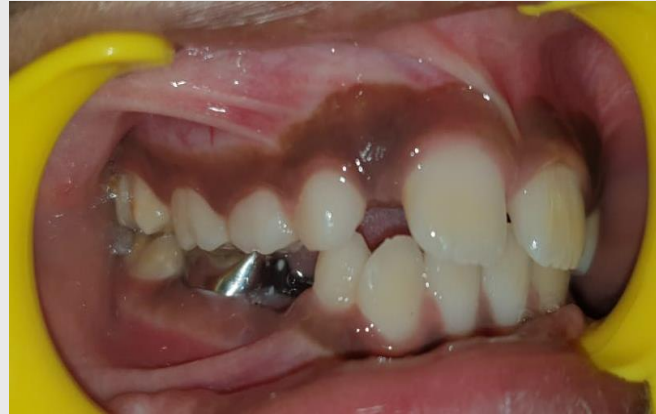PRE OP OCCLUSAL VIEW



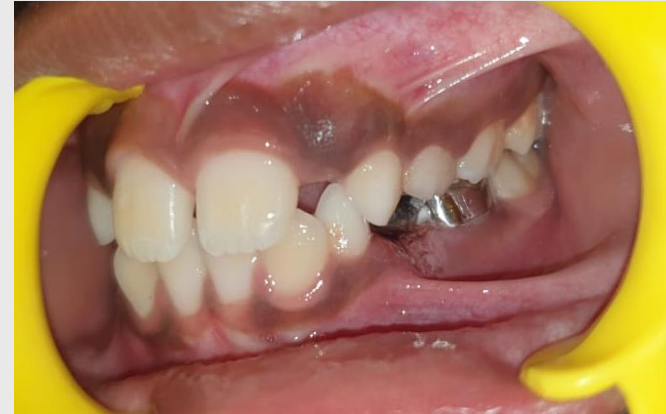POST OP OCCLUSAL VIEW



POST OP FRONTAL VIEW

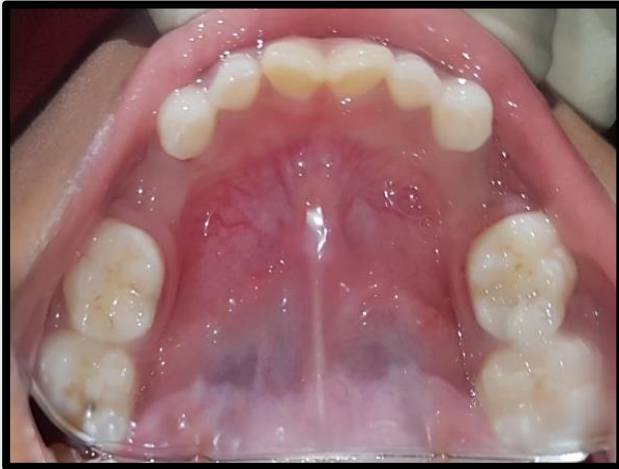

POST OP RIGHT LATERAL VIEW

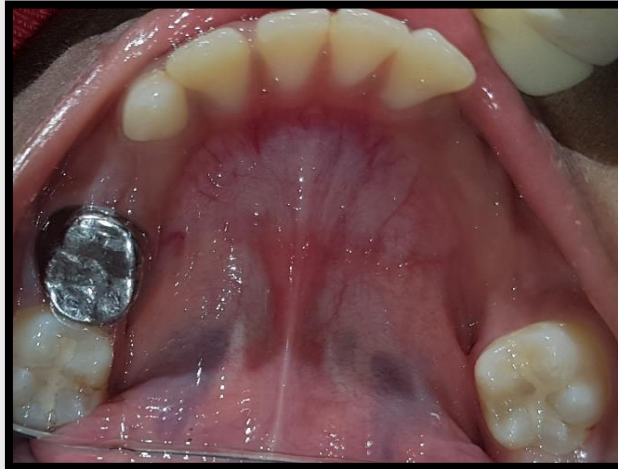

POST OP LEFT LATERAL VIEW

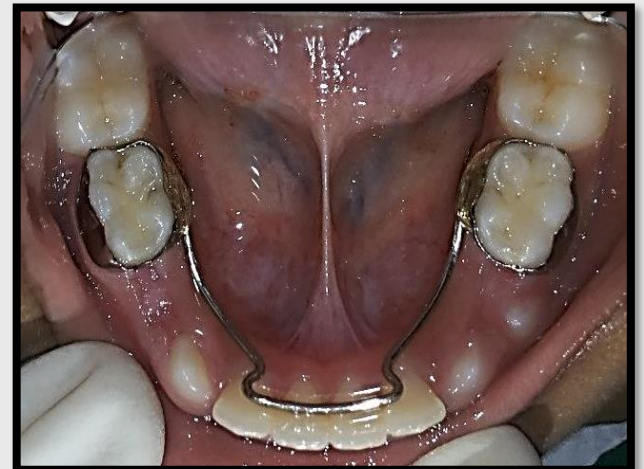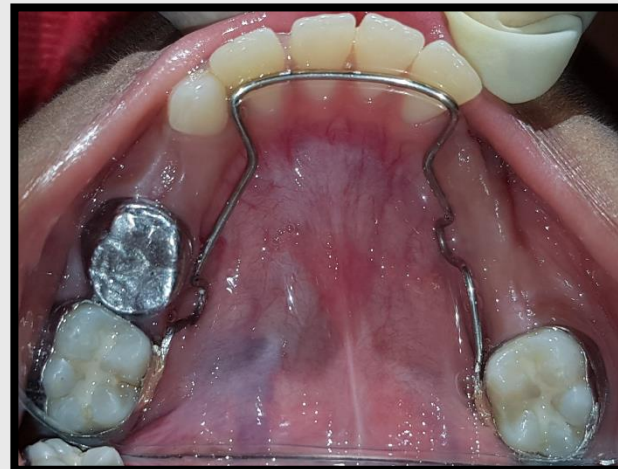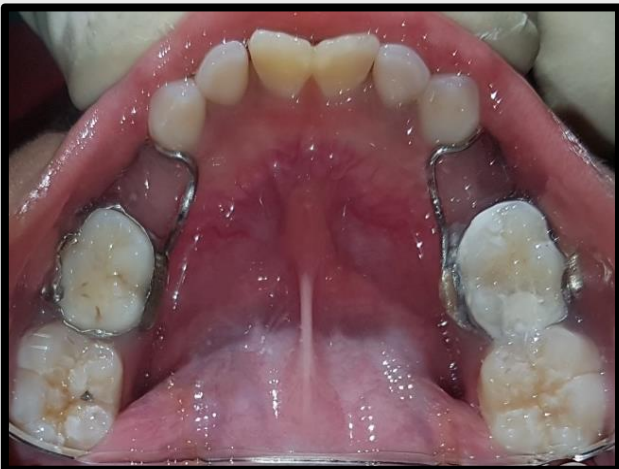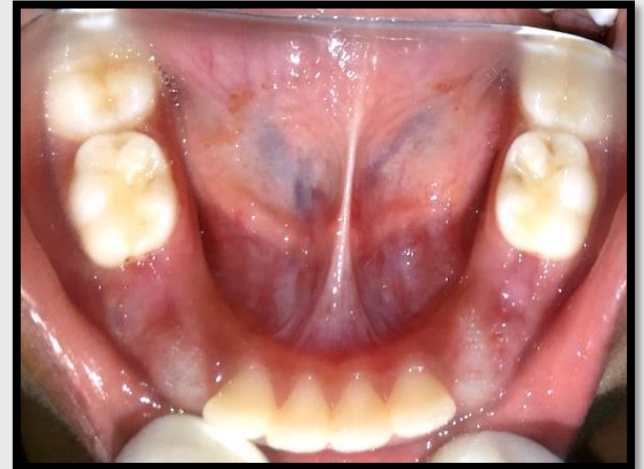BILATERAL BAND LOOP



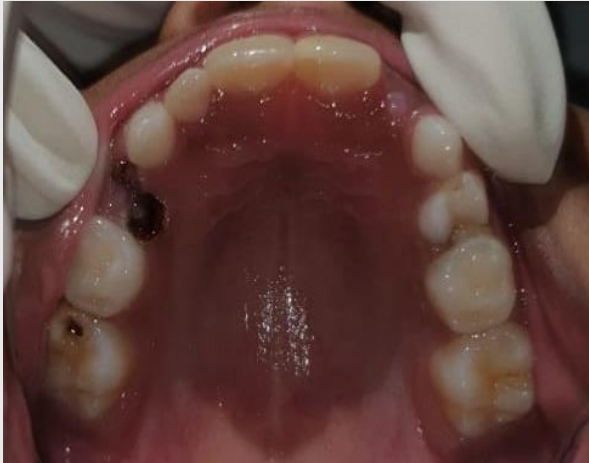LINGUAL ARCH WITH U LOOP



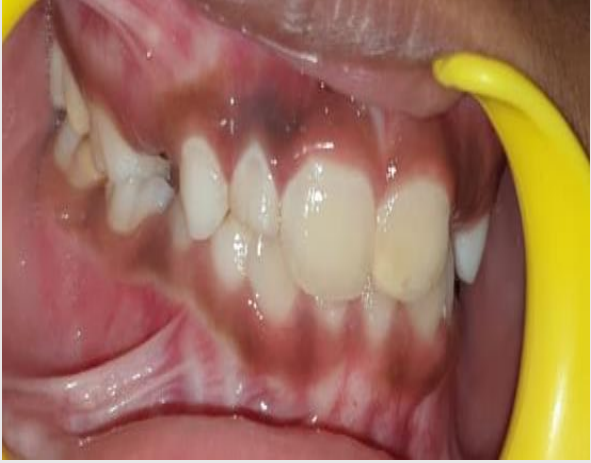LINGUAL ARCH



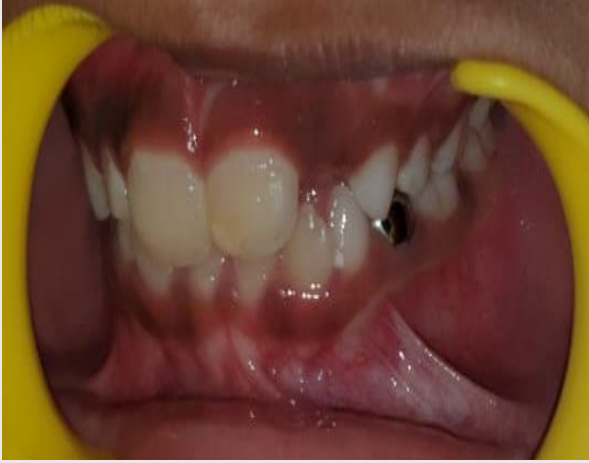NANCE PALATAL ARCH SPACE MAINTAINER



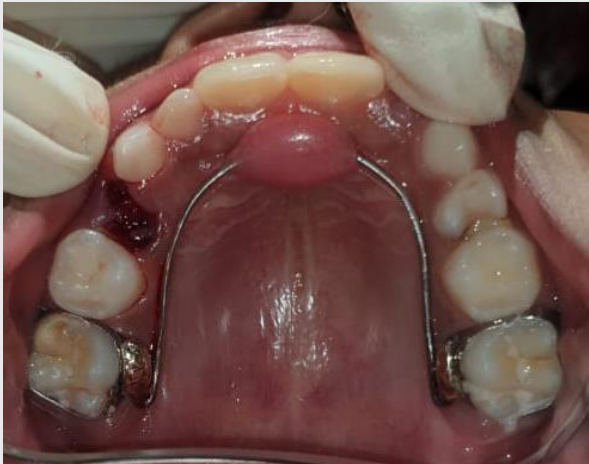PRE OP OCCLUSAL VIEW



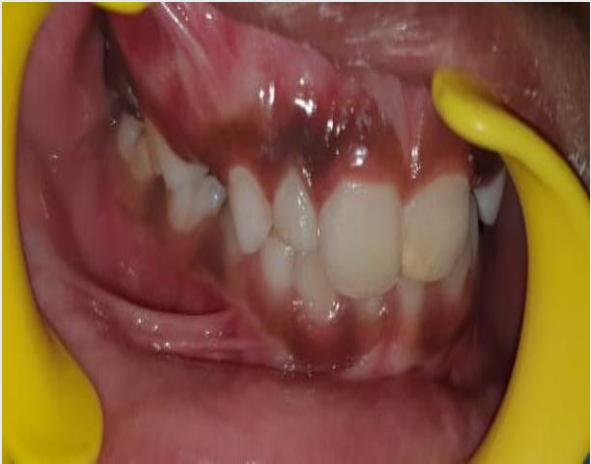PRE OP RIGHT LATERAL VIEW



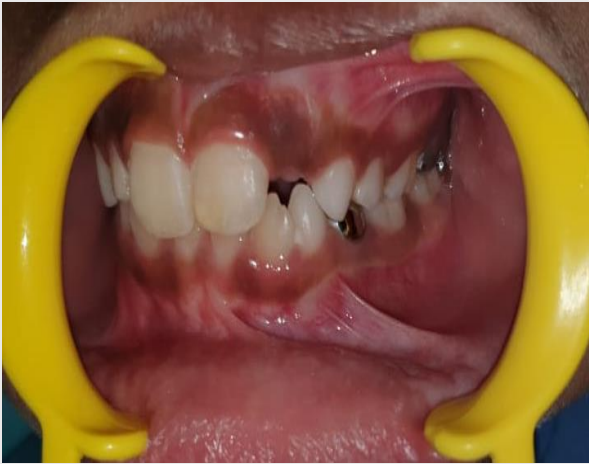PRE OP LEFT LATERAL VIEW



POST OP OCCLUSAL VIEW

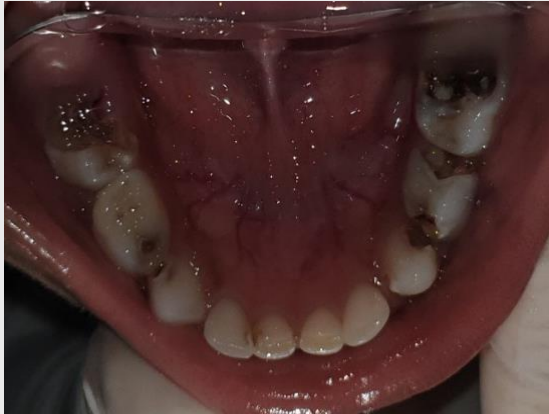

POST OP RIGHT LATERAL VIEW

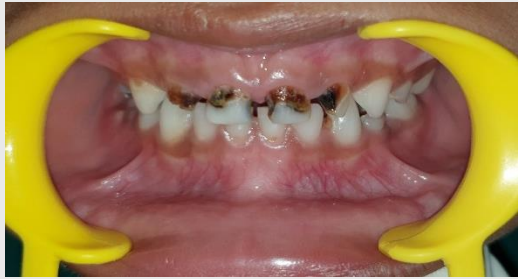

POST OP LEFT LATERAL VIEW

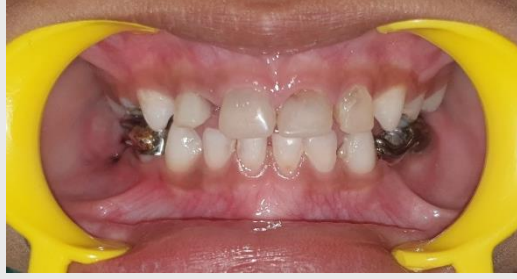DISTAL SHOE SPACE MAINTAINER



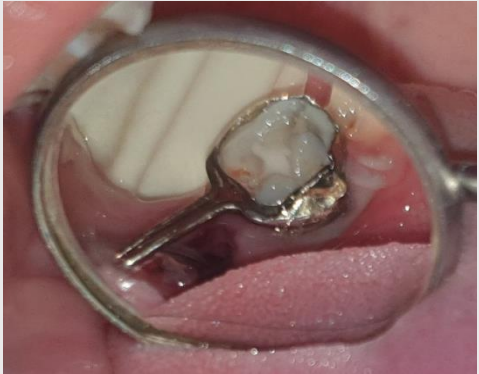PRE OP OCCLUSAL VIEW



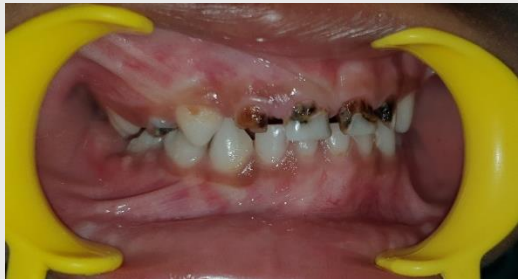PRE OP FRONTAL VIEW



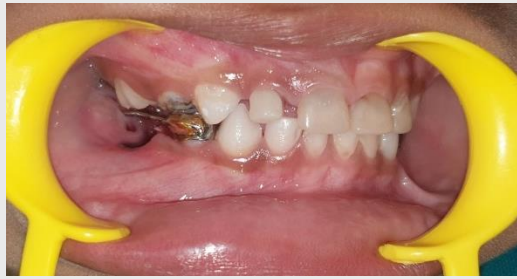POST OP FRONTAL VIEW



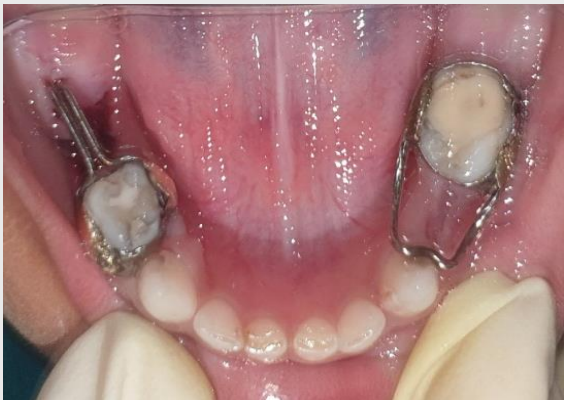DISTAL SHOE



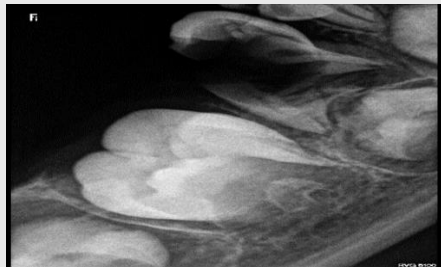
PRE OP RIGHT LATERAL VIEW



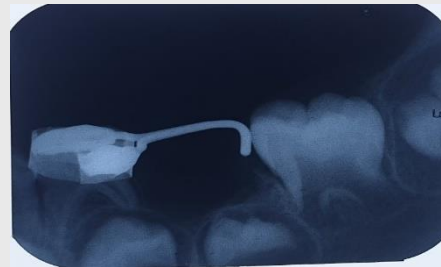
POST OP RIGHT LATERAL VIEW



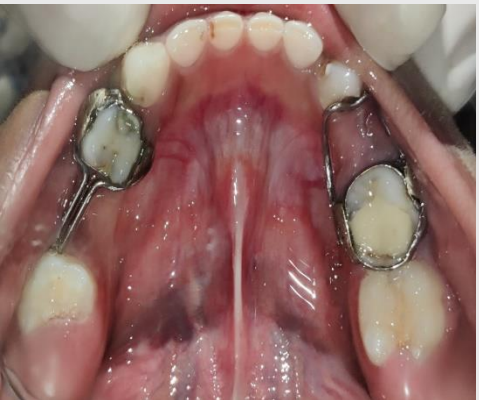POST OP OCCLUSAL VIEW



PRE OP PERIAPICAL RADIOGRAPH



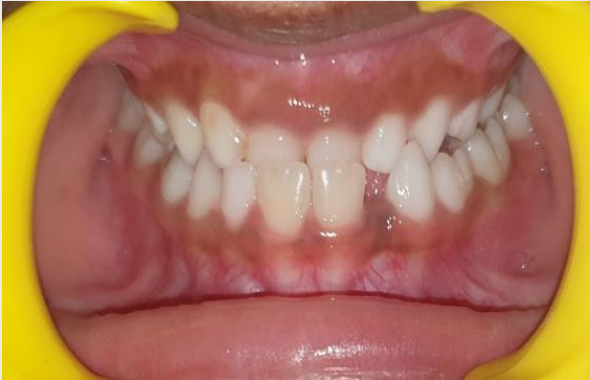POST OP PERIAPICAL RADIOGRAPH



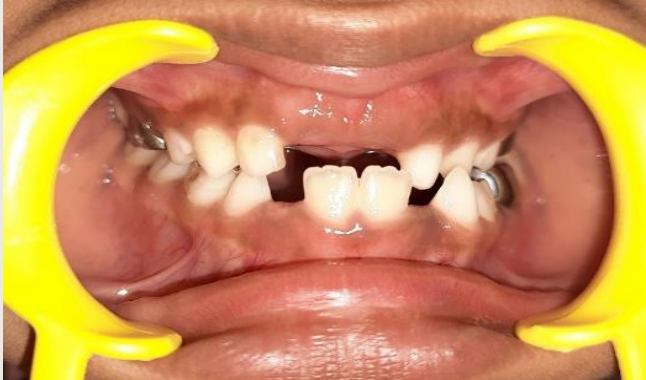5 MONTH FOLLOW UP

INTERCEPTIVE ORTHODONTICS

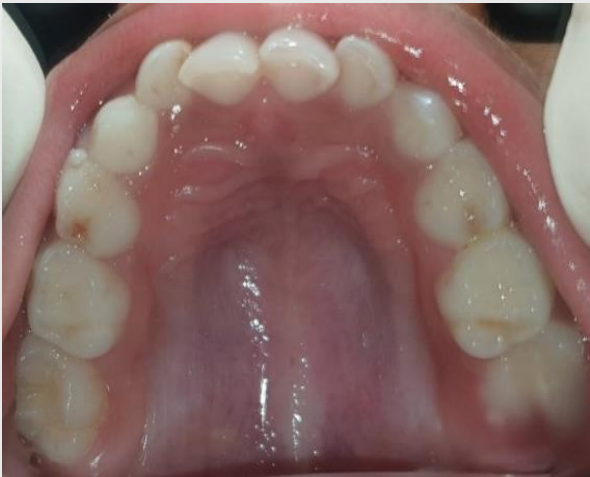QUAD HELIX APPLIANCE



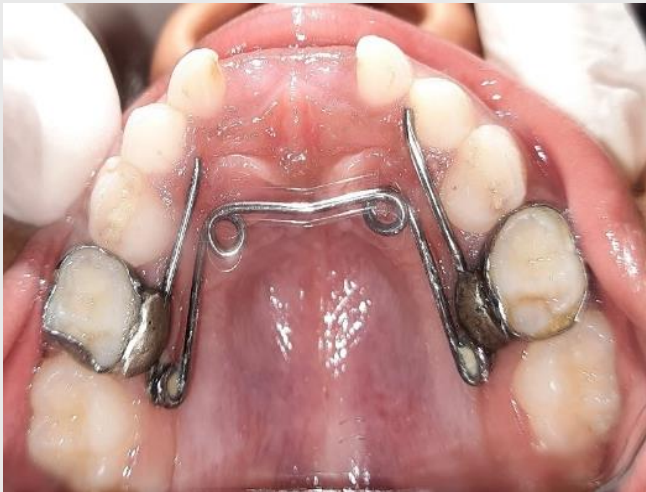PRE OP FRONTAL VIEW



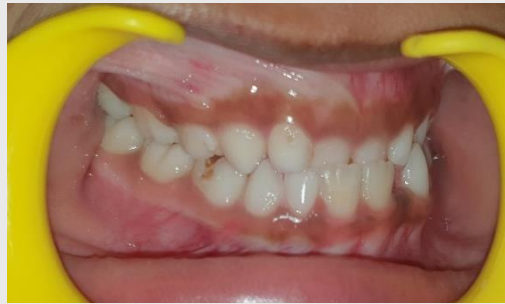POST OP FRONTAL VIEW



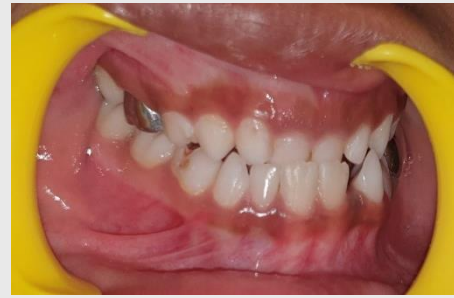PRE OP OCCLUSAL VIEW



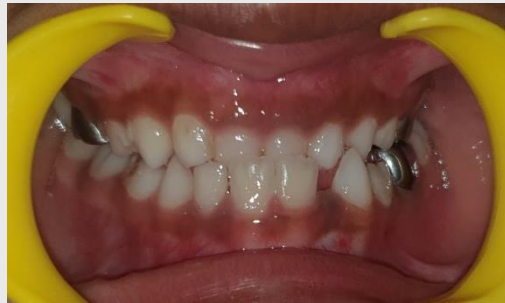POST OP



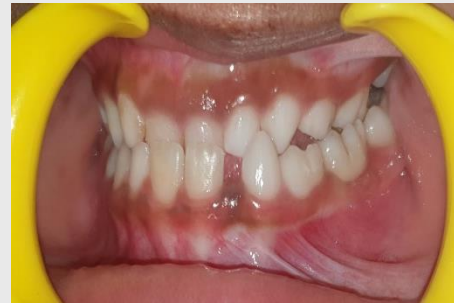PRE OP RIGHT LATERAL VIEW



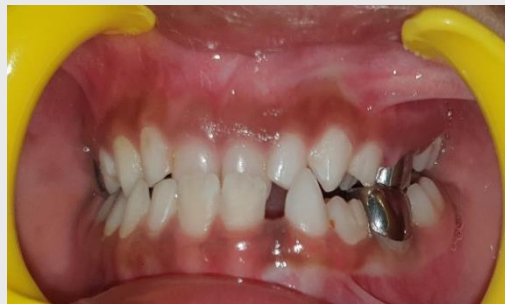1ST ACTIVATION



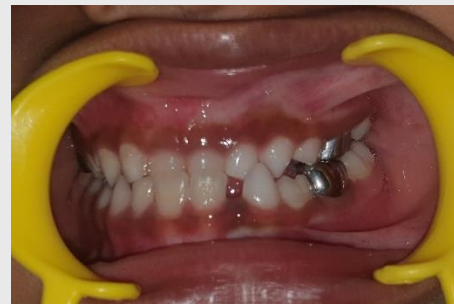2ND ACTIVATION



PRE OP LEFT LATERAL VIEW

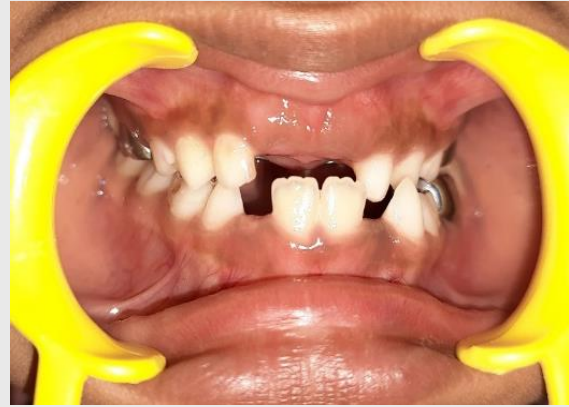

1ST ACTIVATION

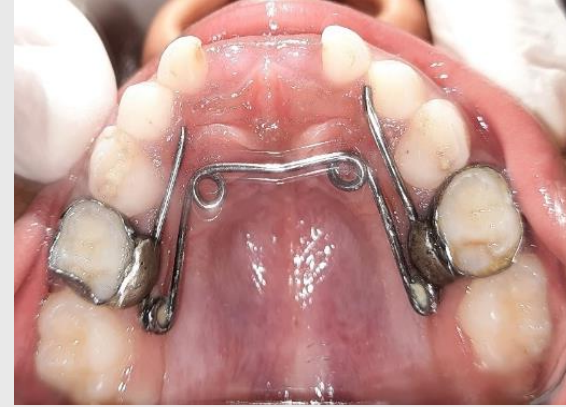

2ND ACTIVATION

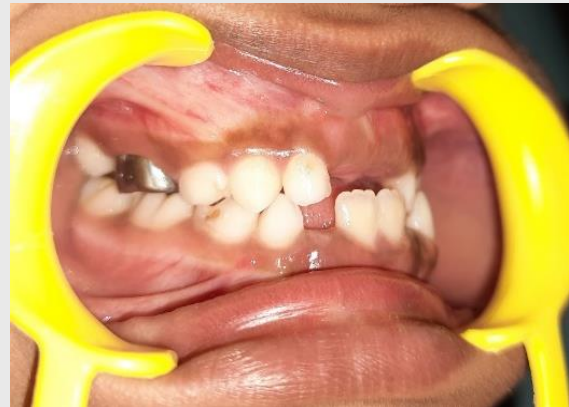5 MONTH FOLLOW UP



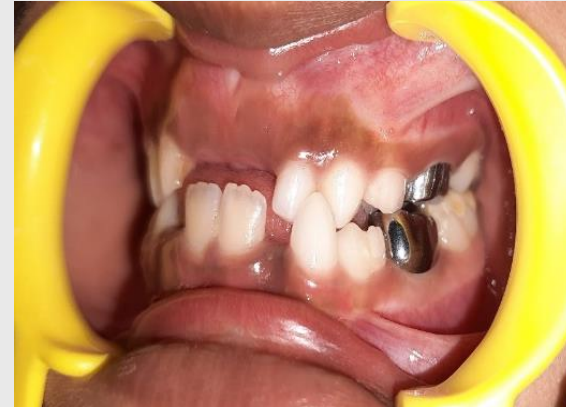FRONTAL VIEW



OCCLUSAL VIEW

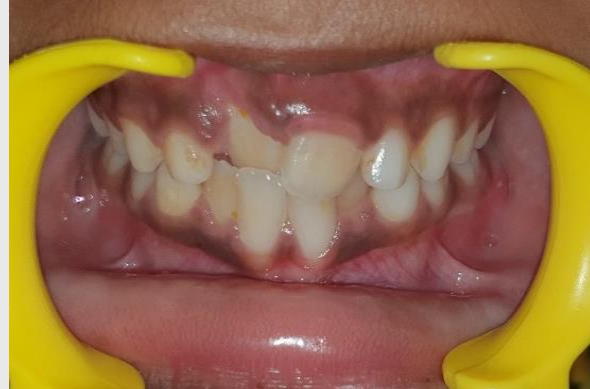

RIGHT LATERAL VIEW

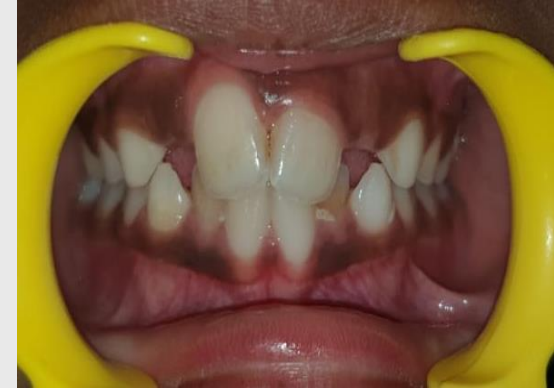

LEFT LATERAL VIEW

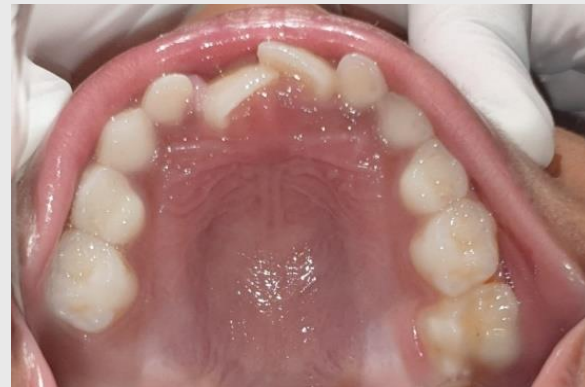CORRECTION OF DEVELOPING ANTERIOR CROSS BITE



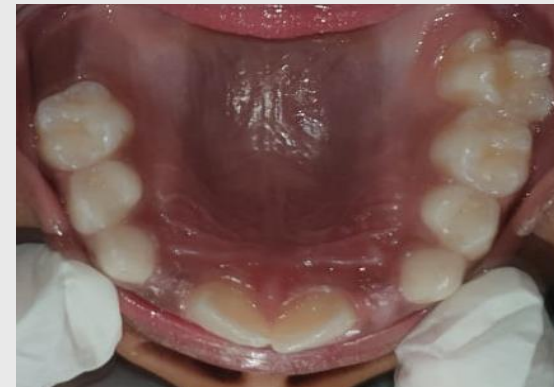PRE OP FRONTAL VIEW



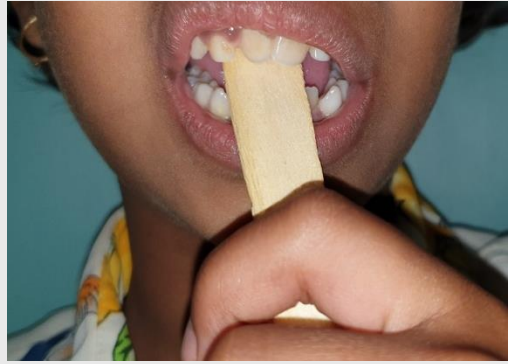POST OP FRONTAL VIEW



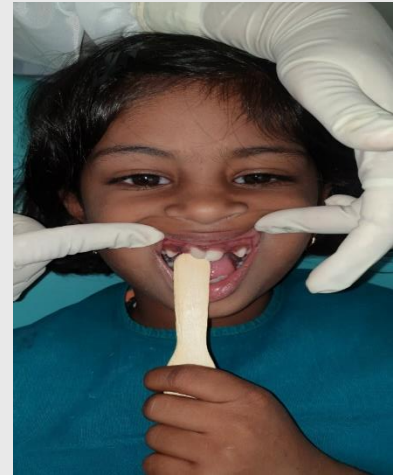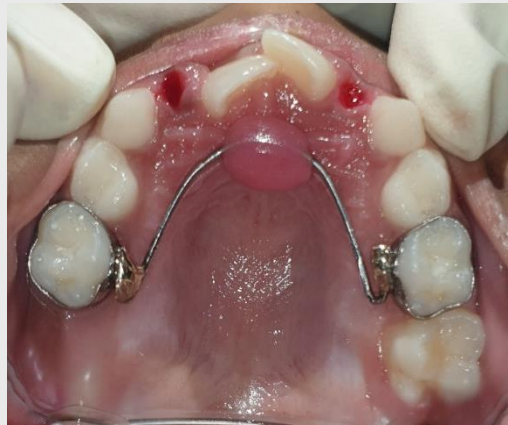PRE OP OCCLUSAL VIEW



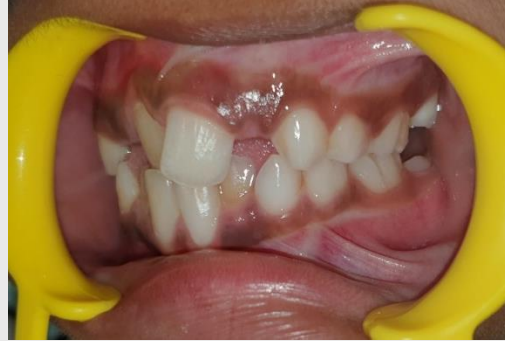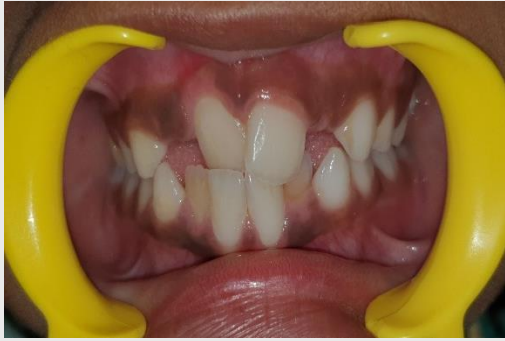POST OP OCCLUSAL VIEW



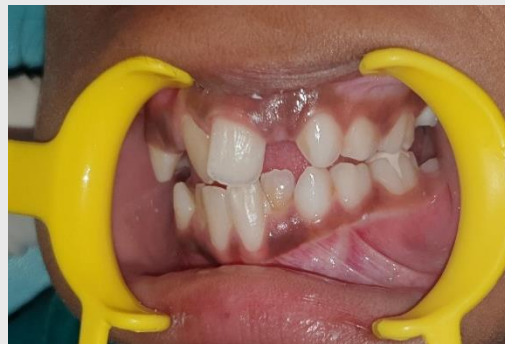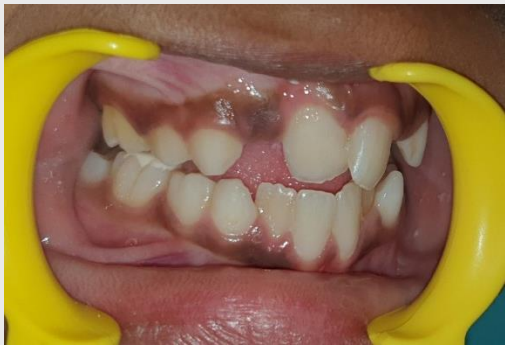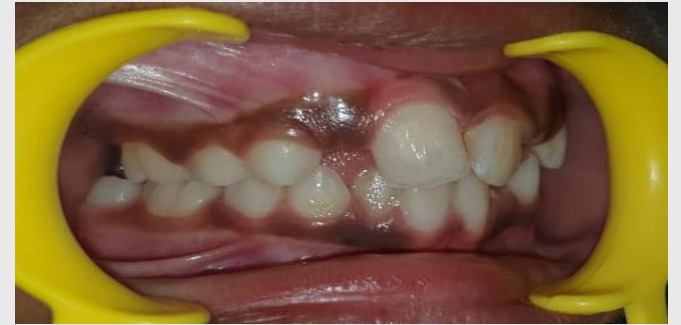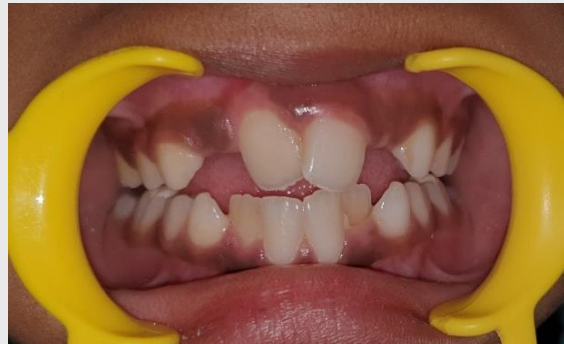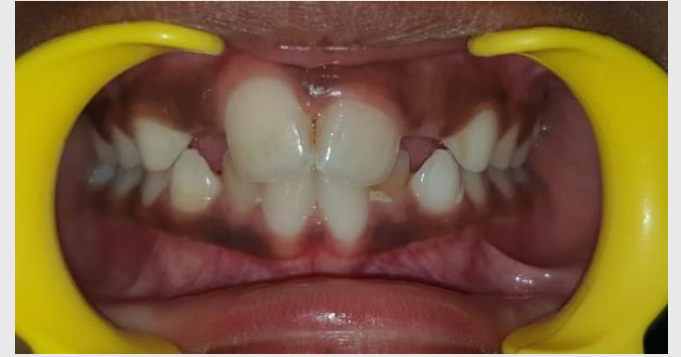TONGUE BLADE THERAPY ADVISED



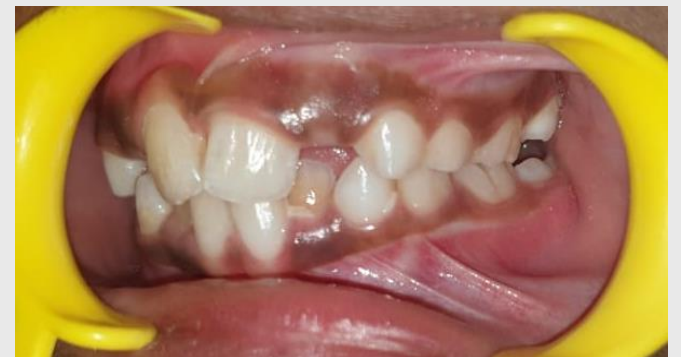EXTRACTION OF LATERAL INCISORS TO CREATE SPACE FOLLOWED BY NANCE TO STABILIZE THE ARCH AND CONTINUATION OF TONGUE BLADE THERAPY



NO CHANGE OBSERVED ON FOLLOW UP

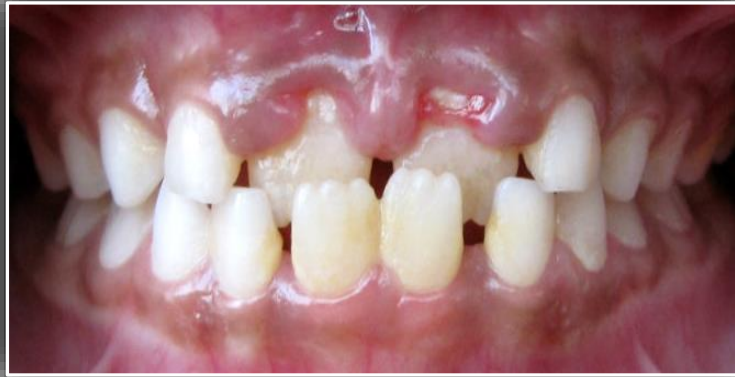

BITE RAISED USING GIC

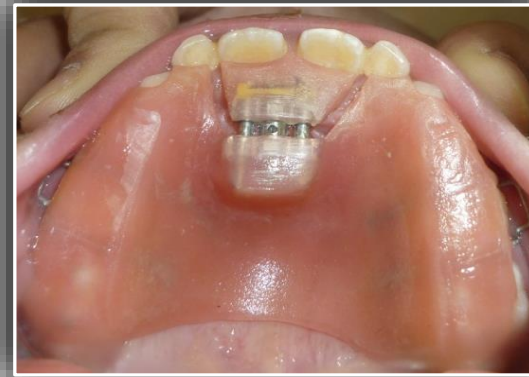

POST OP

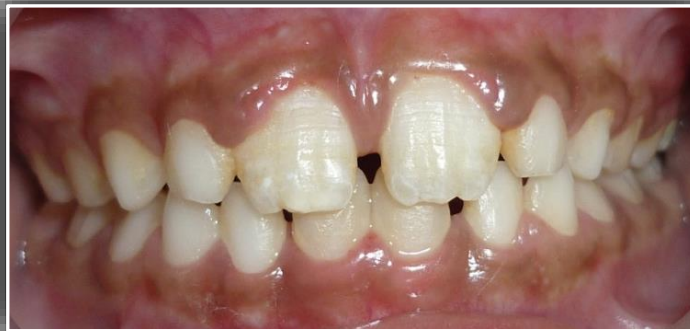Anterior Cross-bite correction using Jackson Expansion Screw in relation to 11 and 12



Pre Op –Frontal view

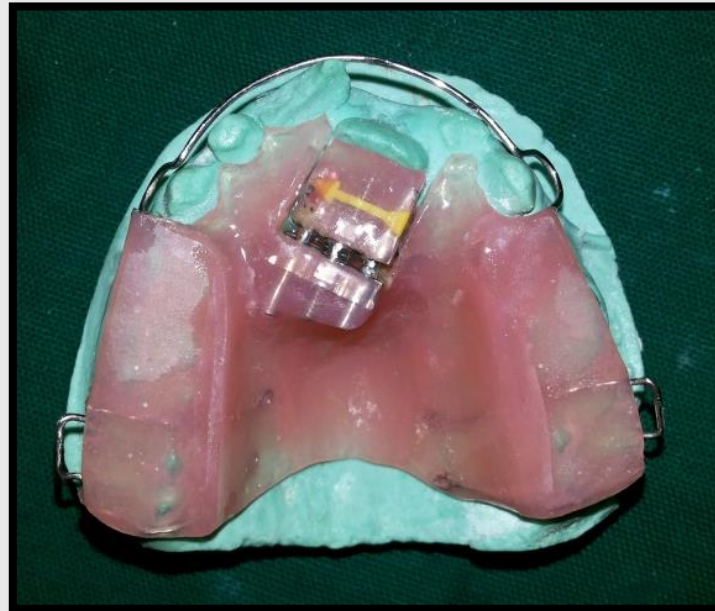
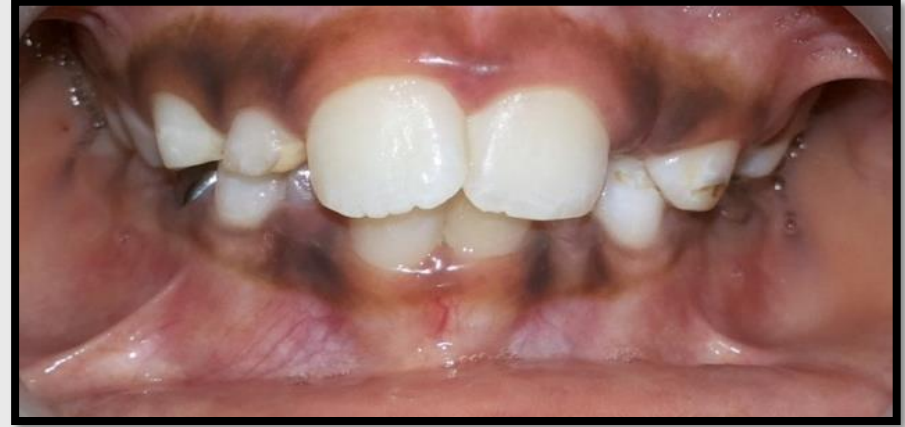
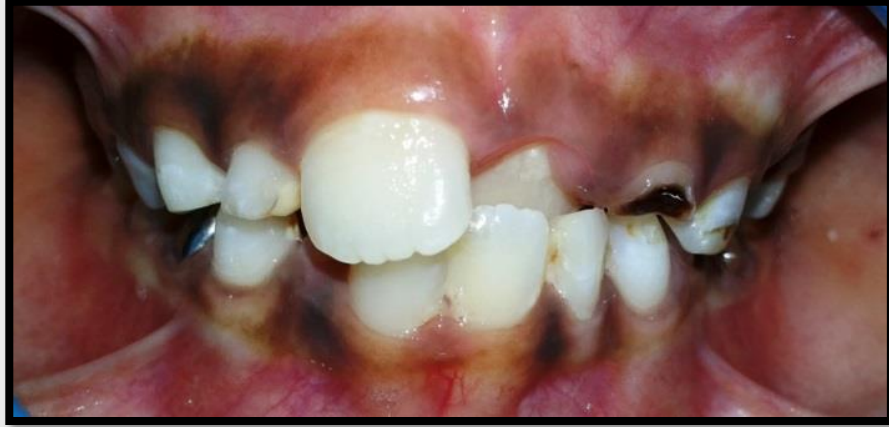
**Jack Screw with
Posterior bite plane**

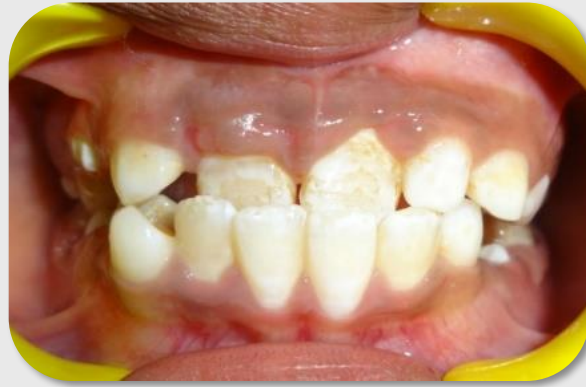

Post Op-Frontal view

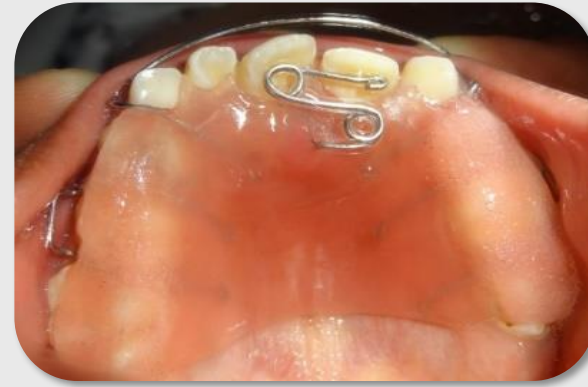Anterior Crossbite



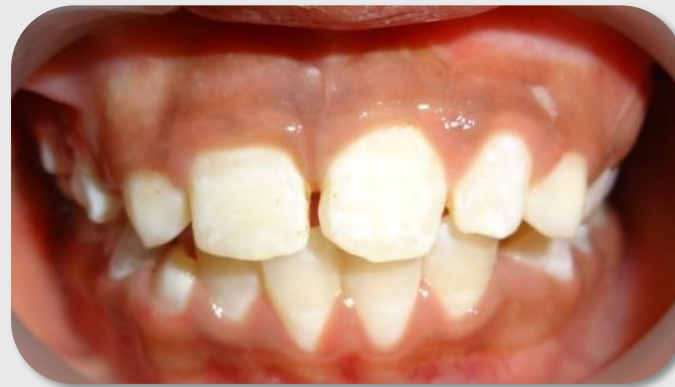Crossbite correction using Posterior bite plane with Double Cantilever Spring



Pre op frontal view



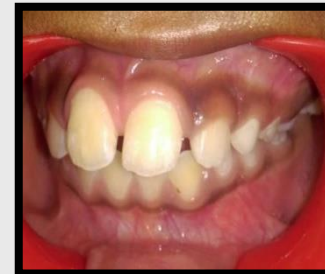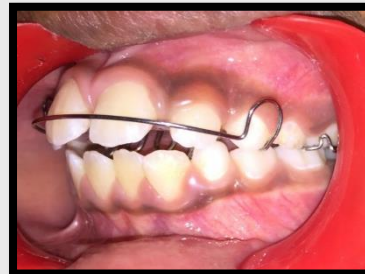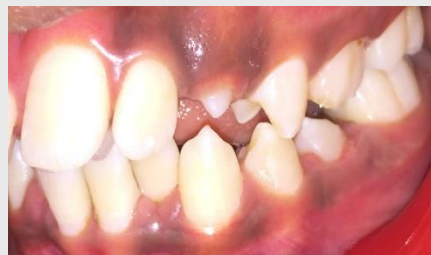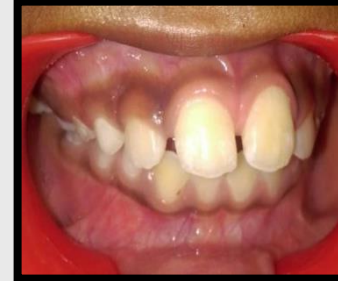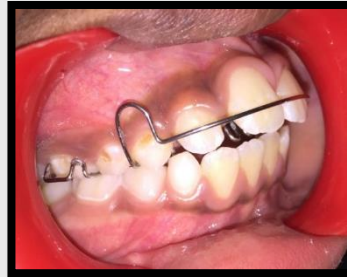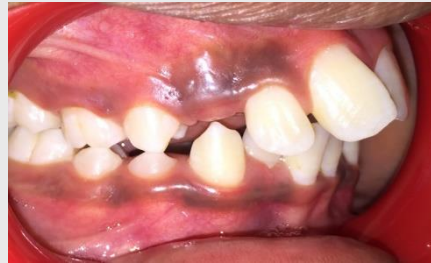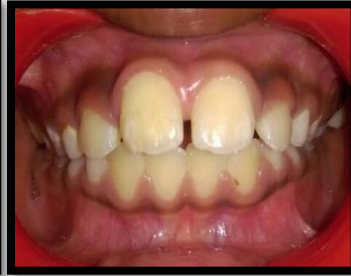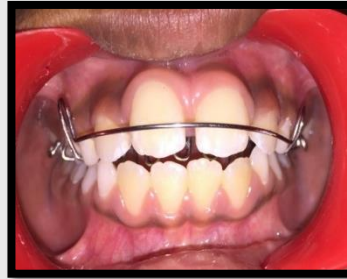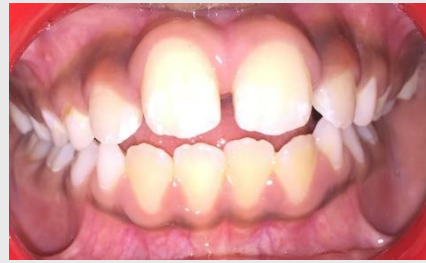Double cantilever spring with
Posterior bite plane



Post op

HABIT BREAKING APPLIANCE

CORRECTION OF TONGUE THRUSTING USING TONGUE CRIB

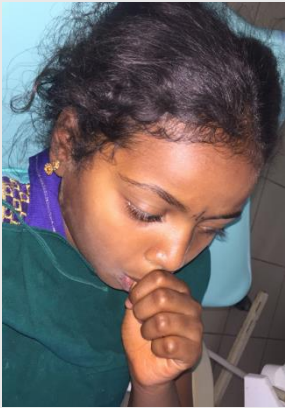

PREOP

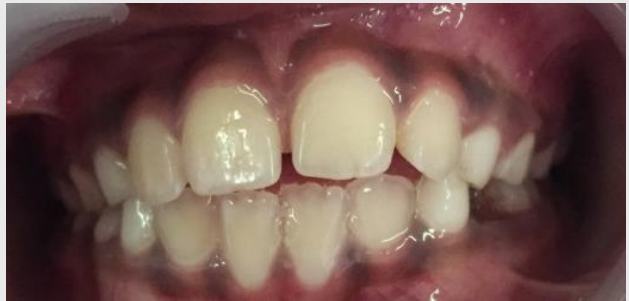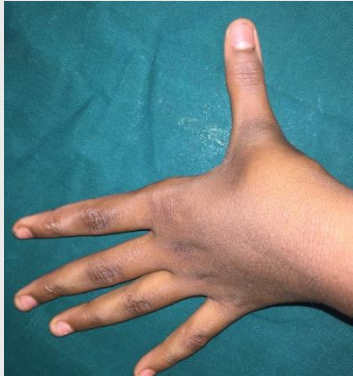TONGUE CRIB

6 MONTHS POST

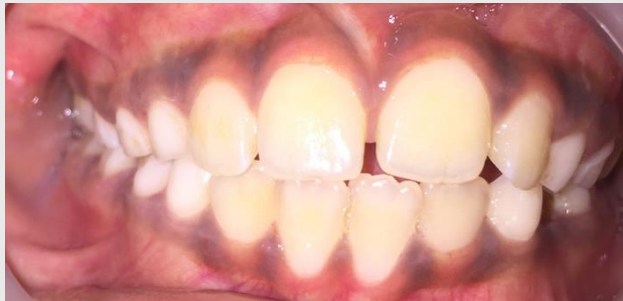Bluegrass appliance for thumbsucking and tongue thrusting habit



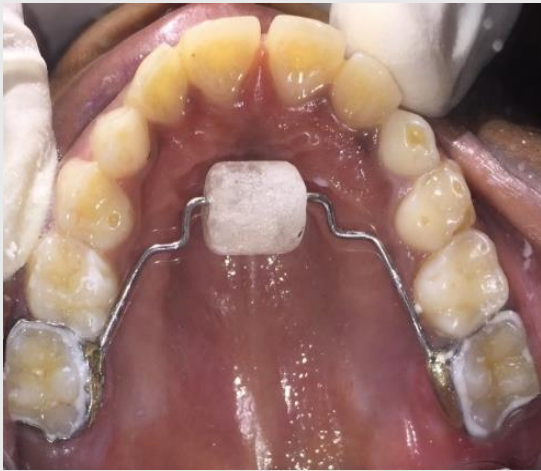Pre op – showing thumb sucking habit and inflamed callus



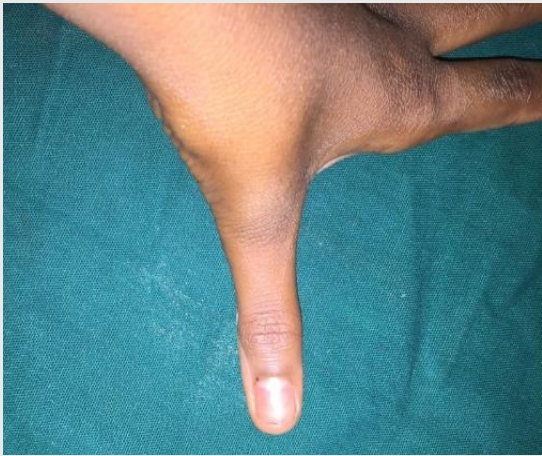Pre op frontal view



At 3 months follow up

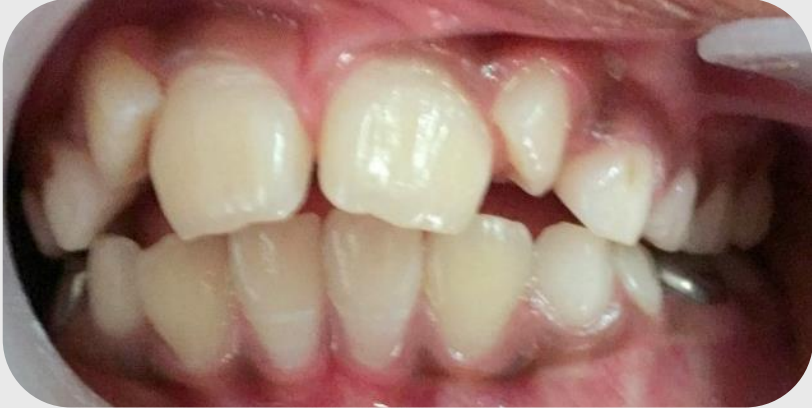

Blue grass appliance delivered



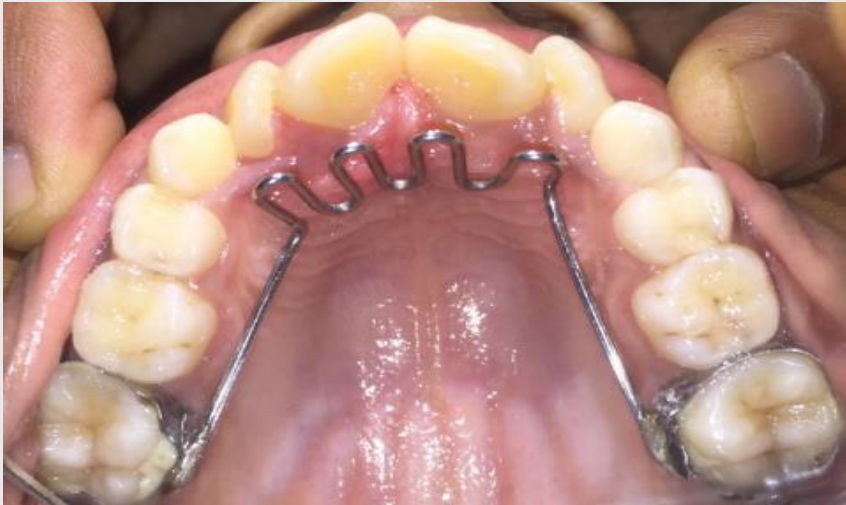Healed callus at 3 months follow up

Tongue thrusting habit

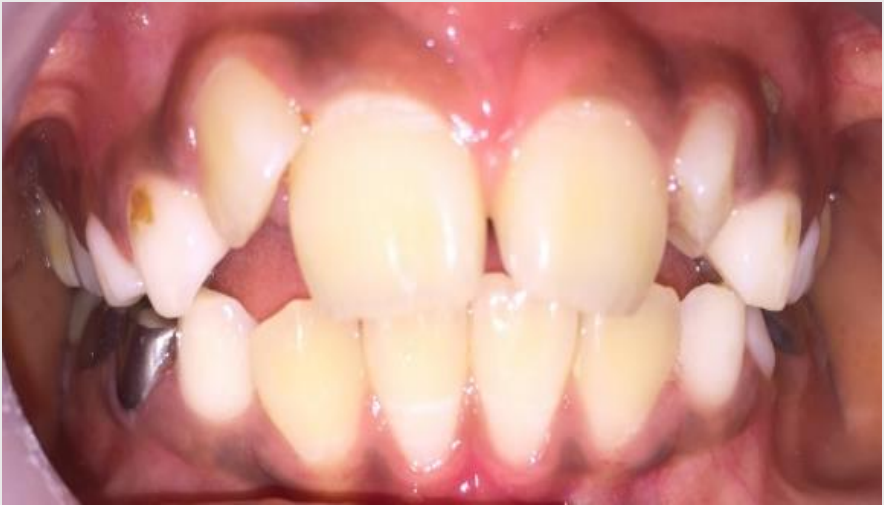

Pre op

Complains of forwardly placed upper front teeth

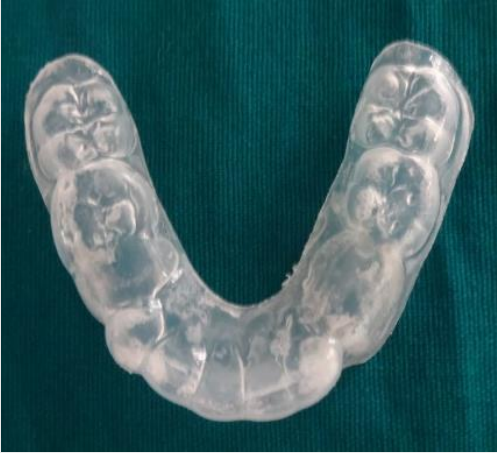
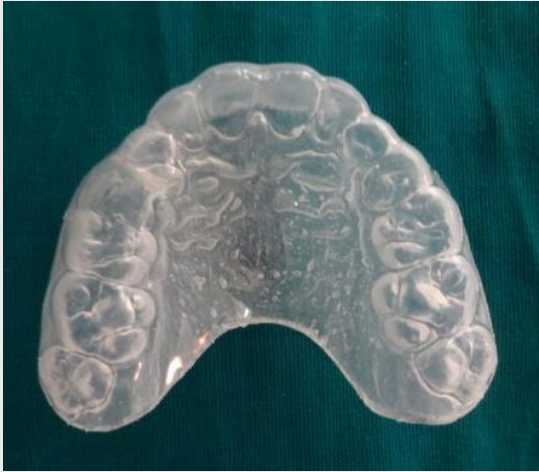
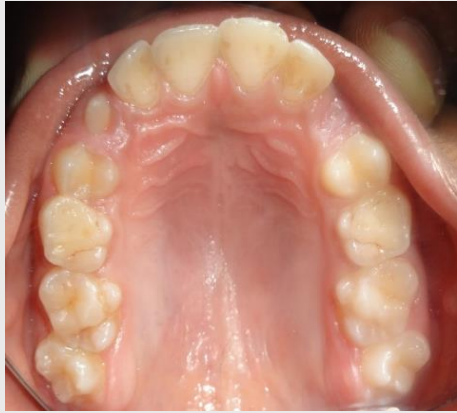Tongue crib delivery

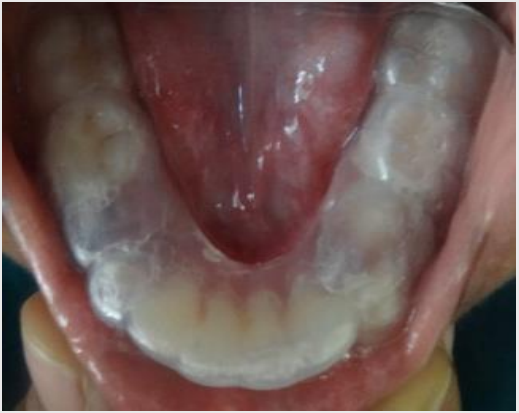
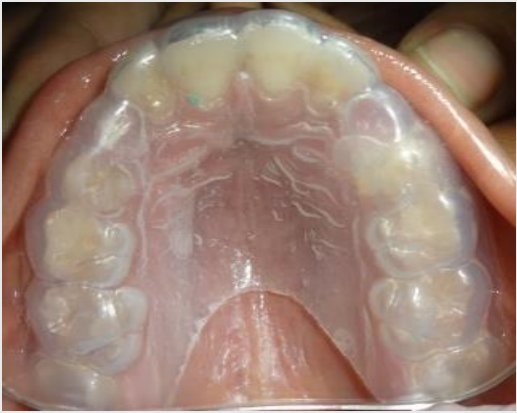
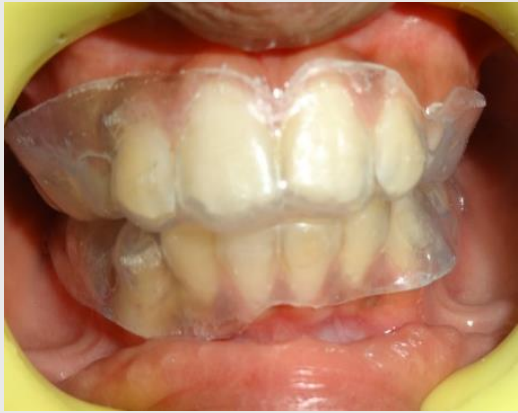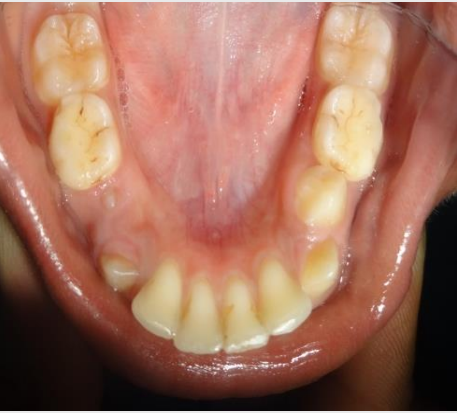At 3 month follow up

MOUTHGUARD FOR BRUXISM

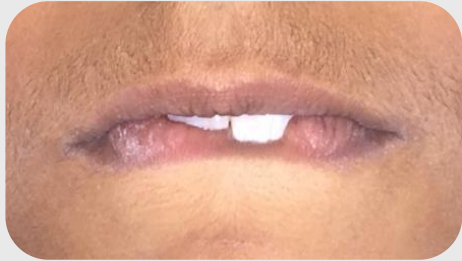

MOUTH GUARD

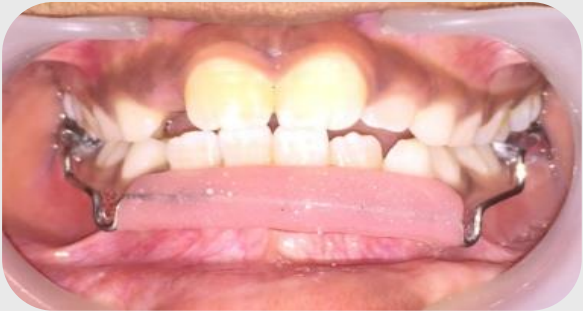

PRE OP
Teeth grinding habit while
studying and night

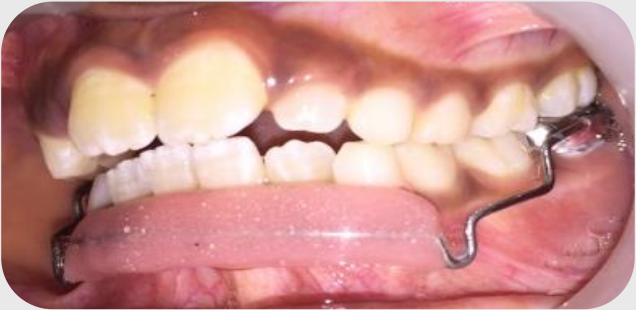Lip bumper appliance for lip biting habit



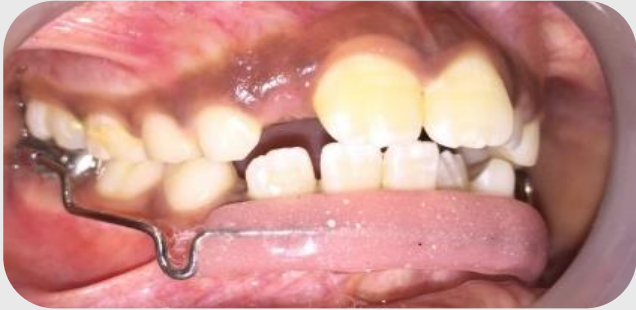Pre op – showing lip biting and hyperactive mentalis



Frontal view following lip bumper delivery



Lateral view 2nd quadrant



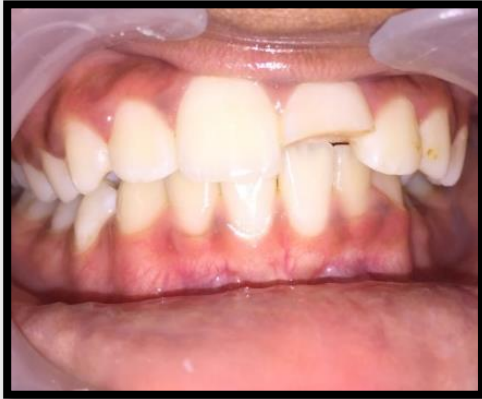Lateral view 1st quadrant



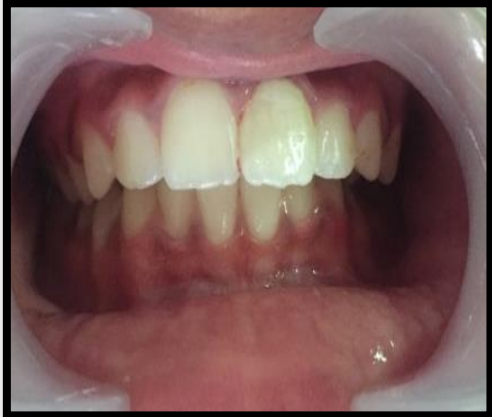After lip bumper removal

**FRAGMENT
REATTACHMENT**

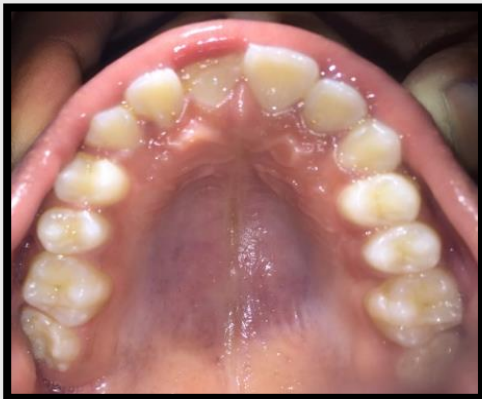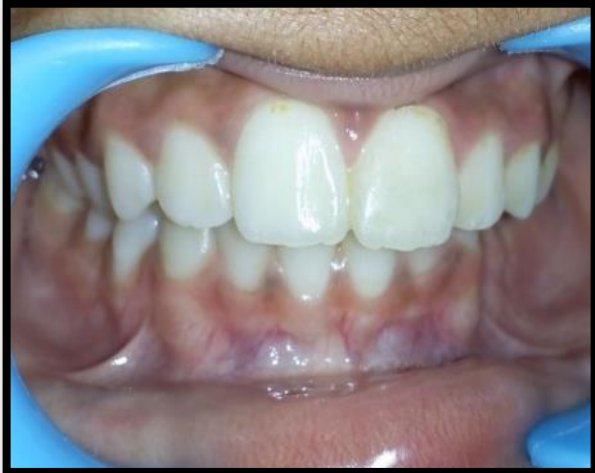Fragment Reattachment with 21: CASE 1



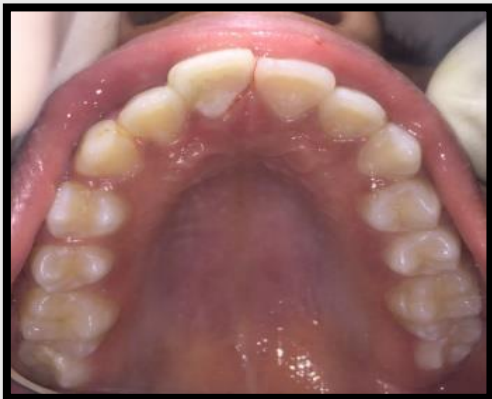Pre Op Frontal view



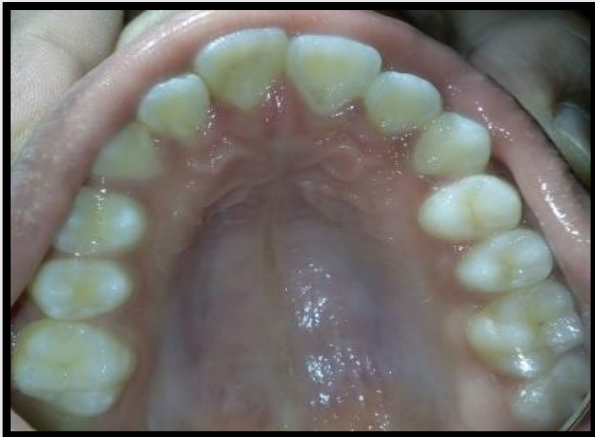Post Op Frontal View



Pre Op Occlusal view

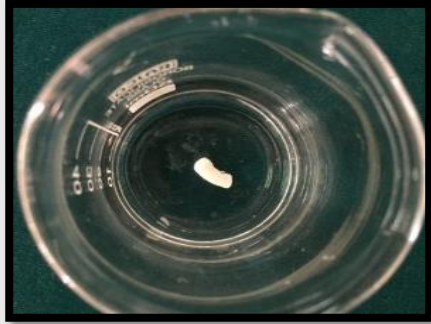

Post Op Occlusal View



3 month follow up

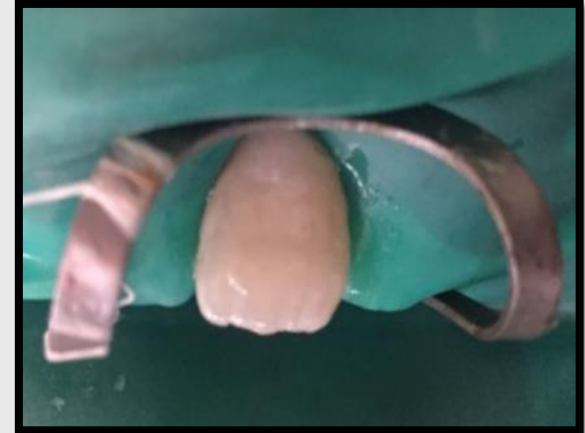PROCEDURE



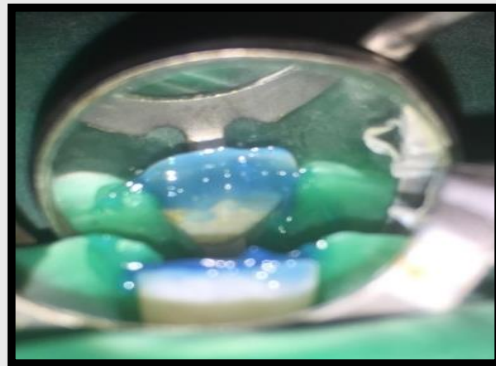
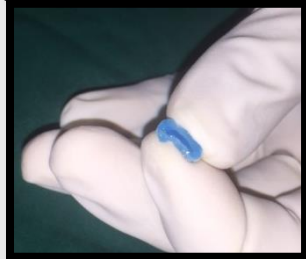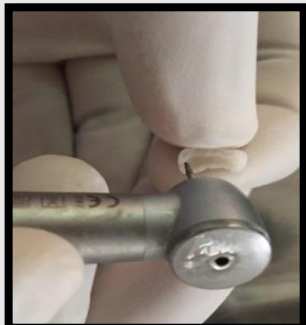
Tooth fragment stored in saline



**Internal groove preparation
on tooth fragment**

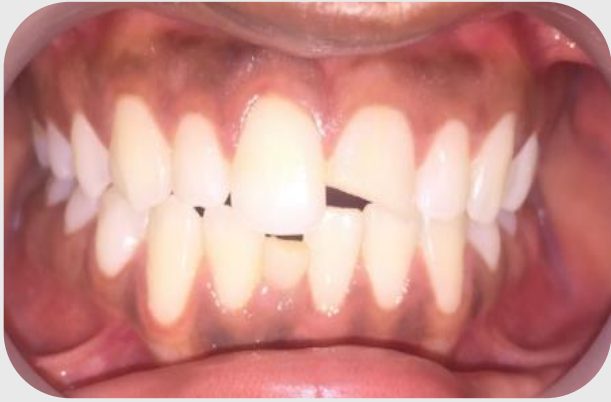

Post Op

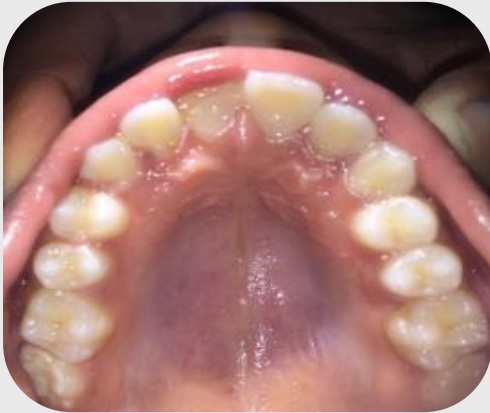

Acid etching

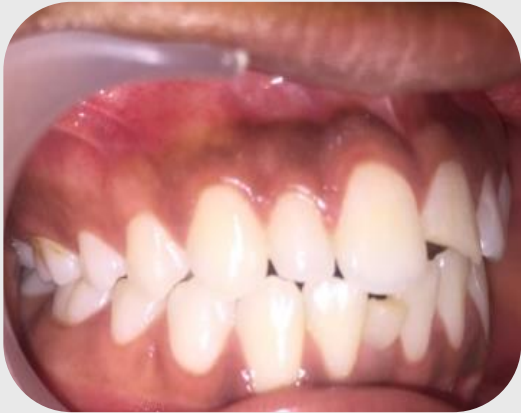Fragment Reattachment irt 21: CASE 2



Pre op frontal view




Pre op Occlusal view



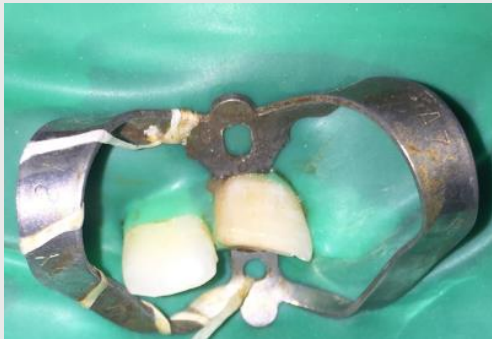Pre op lateral view



Fragment retrieved



Fragment stored in HBSS

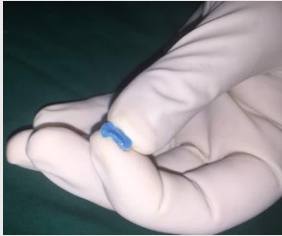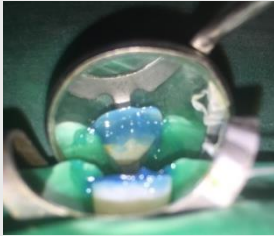


Prior to reattachment

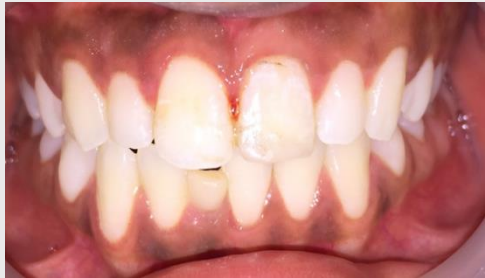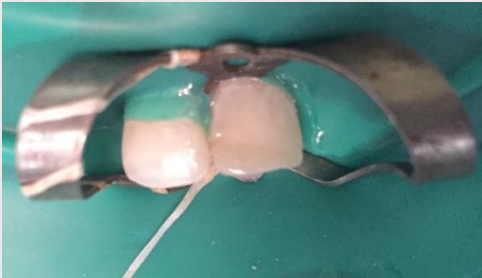PROCEDURE



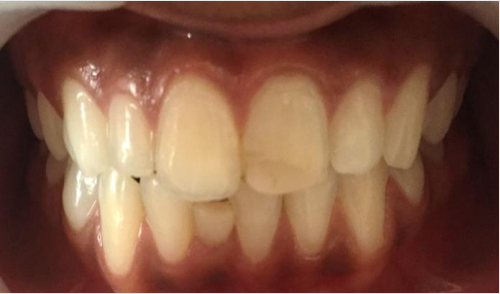Internal dentinal groove preparation



Acid etching of the fractured tooth and Segment using 37% phosphoric acid



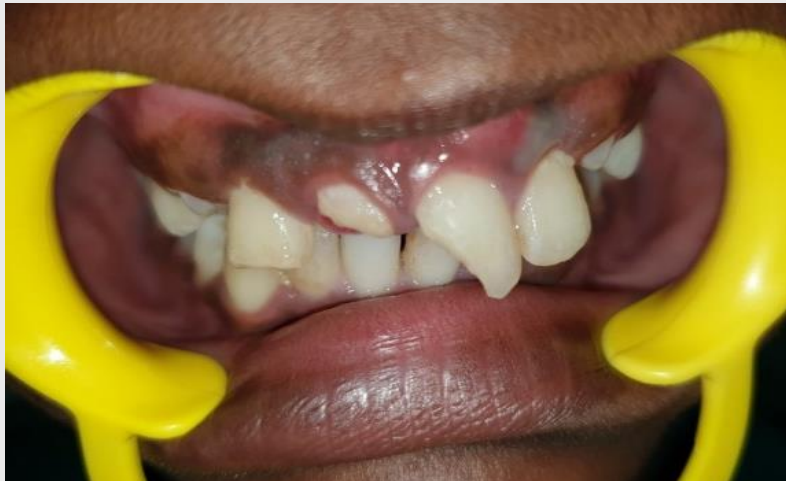Post op following reattachment



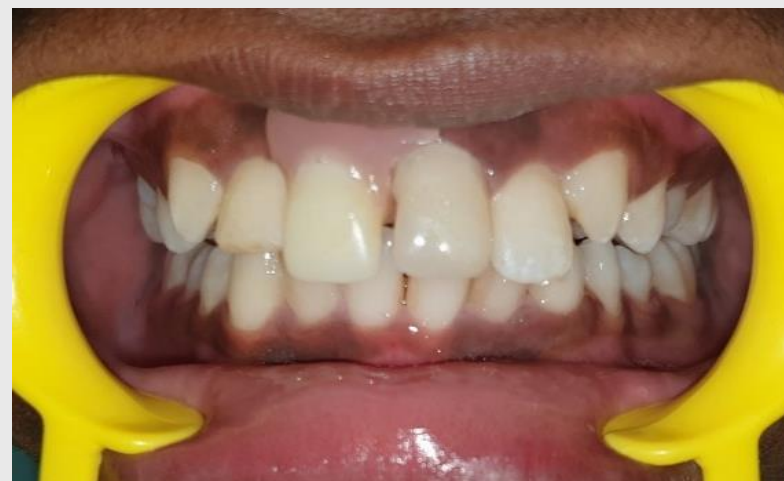Follow up at 6 months follow up

PEDIATRIC PROSTHODONTICS

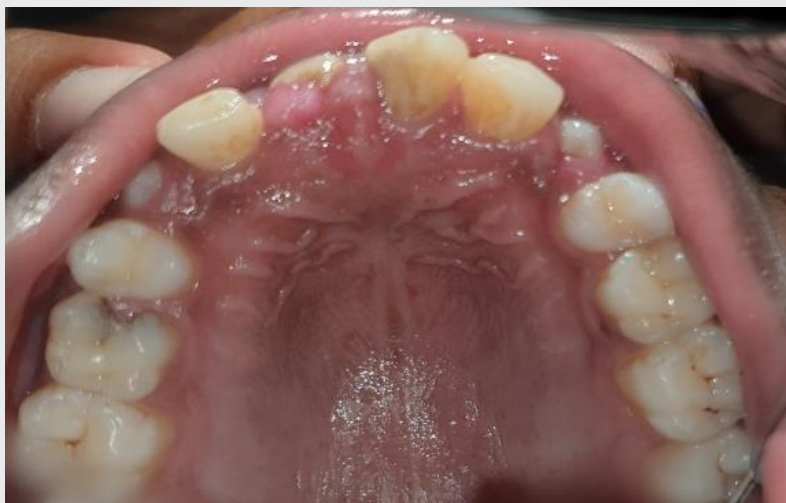REMOVABLE PARTIAL DENTURE IN RELATION TO 11



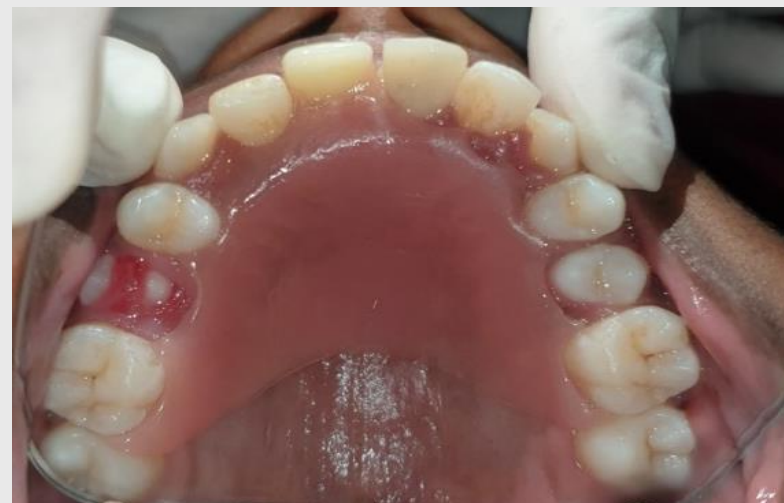PRE OP VIEW 11,21



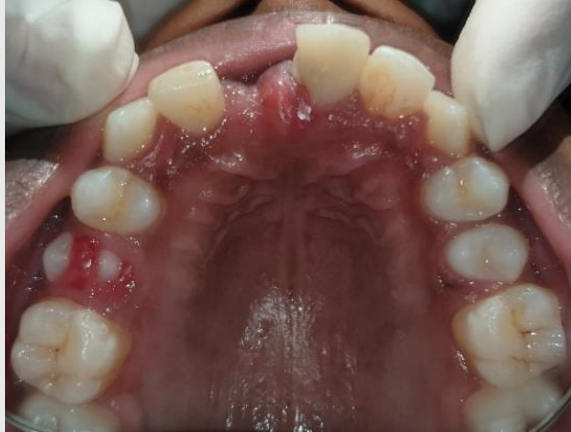POST OP VIEW



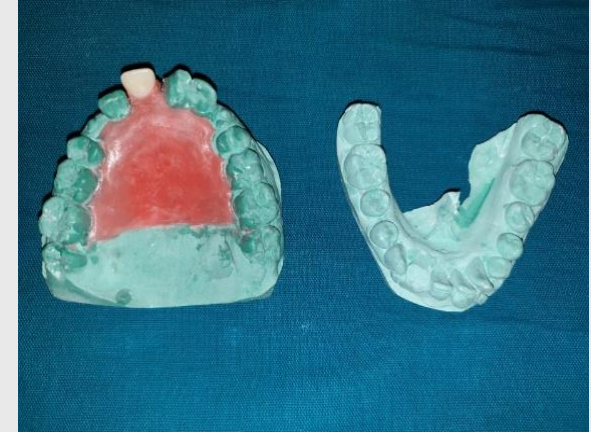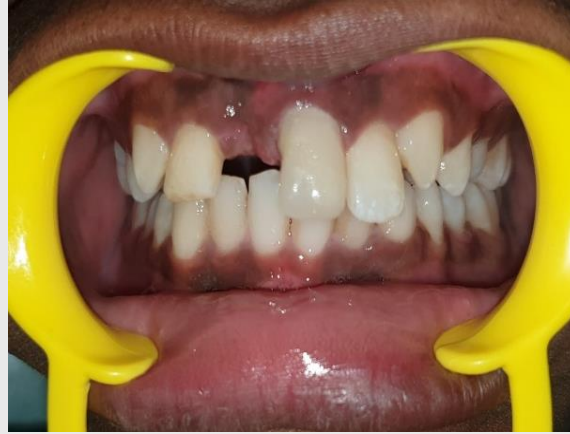PRE OP OCCLUSAL VIEW



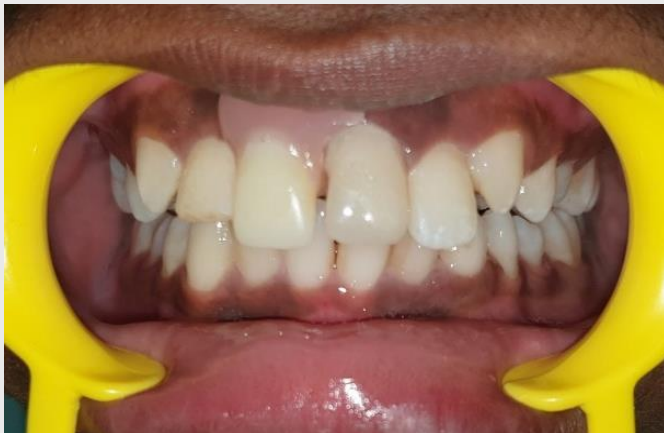POST OP OCCLUSAL VIEW



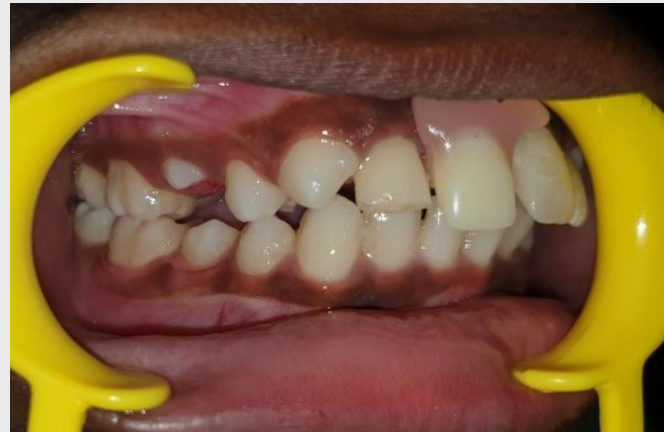Extraction done wrt 11 and strip crown with 21



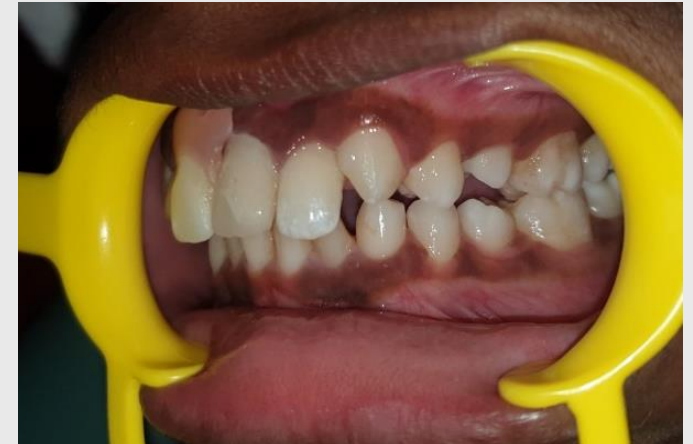Wax up



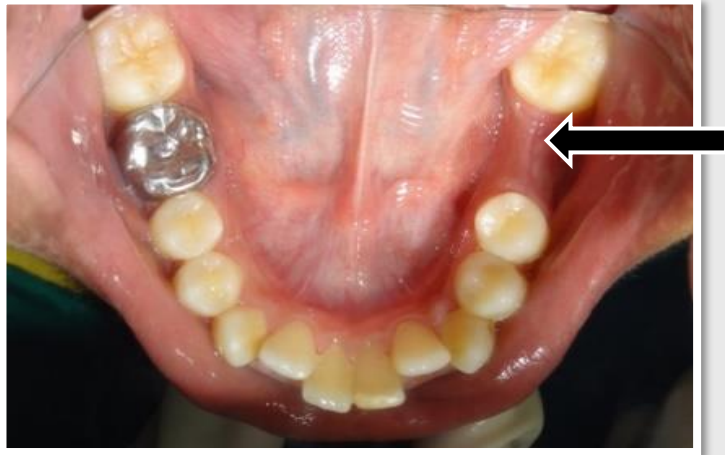
Post insertion frontal view



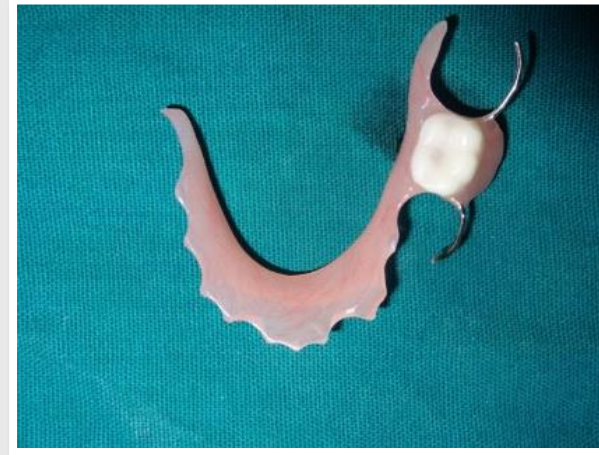Post insertion lateral view



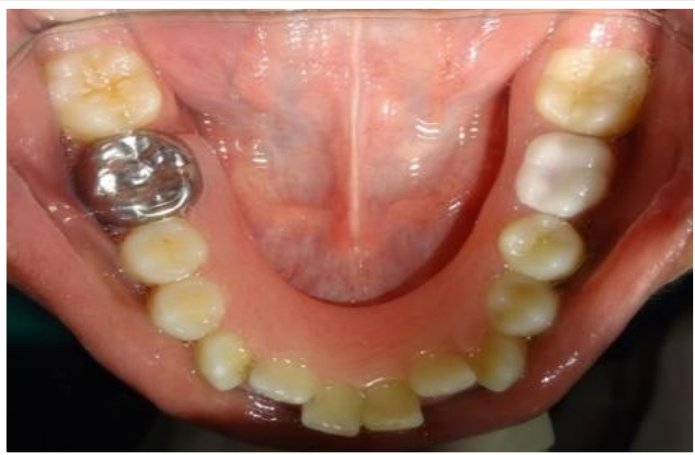Removable partial denture i.r.t 36



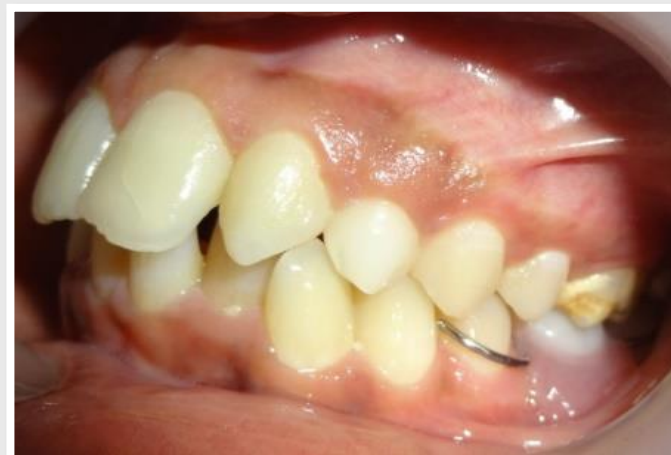Pre op – occlusal view



RPD in relation to 36

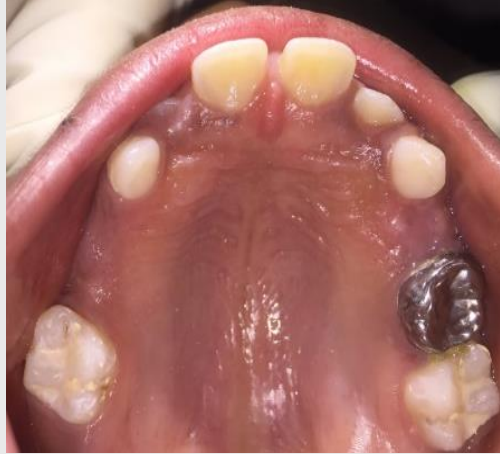

Post op

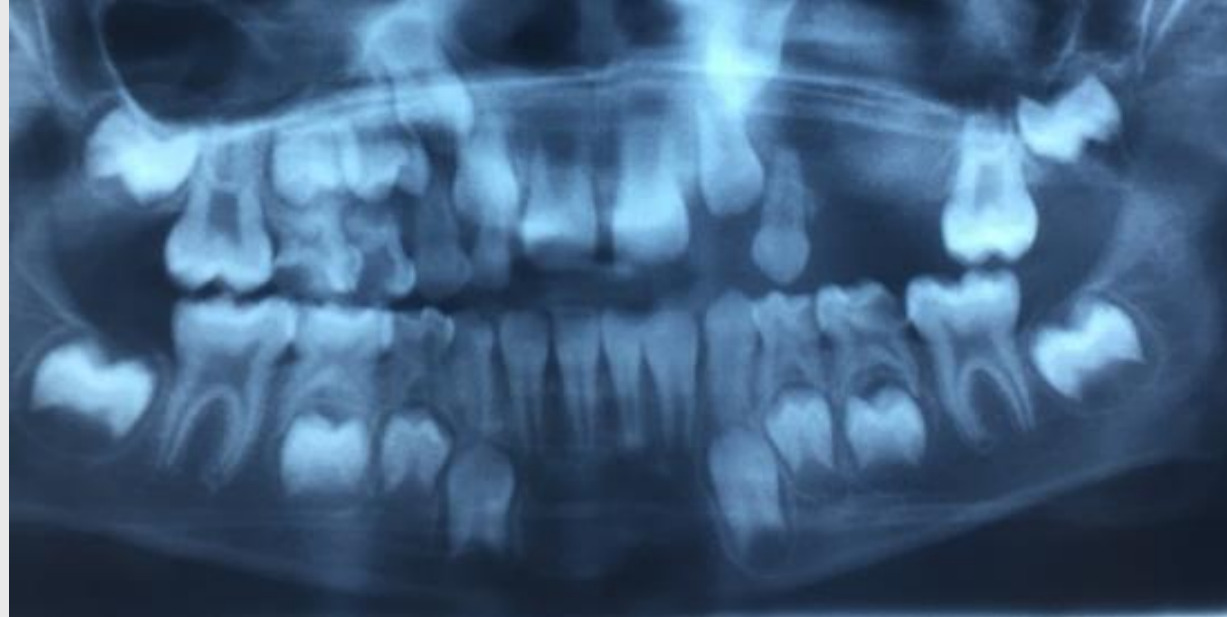

Post op

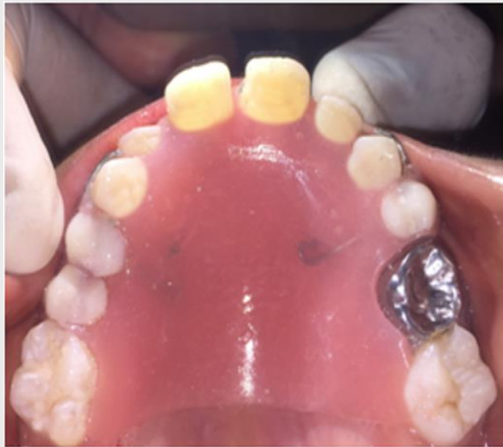Removable partial denture i.r.t 14,24,25



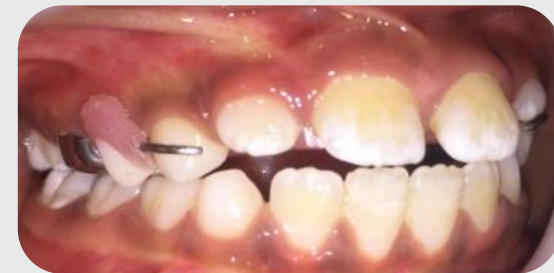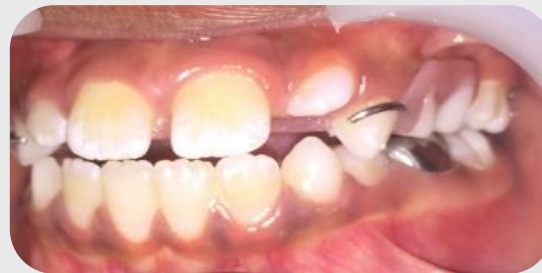Pre op – occlusal view



Missing tooth bud irt 24,25

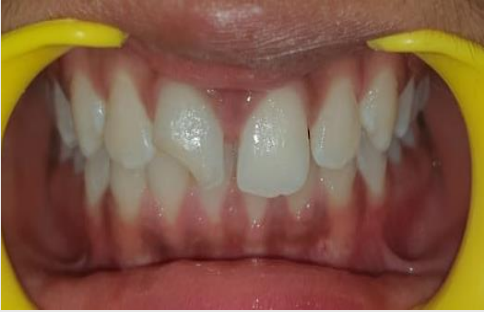

RPD irt missing 24,24 and unerupted 14

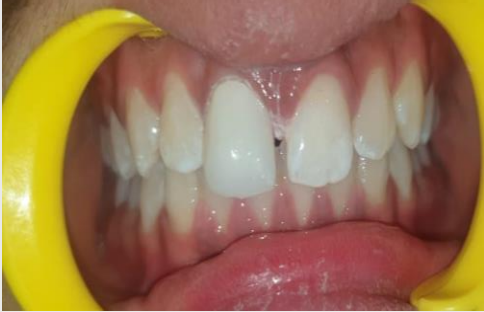

Lateral view following denture

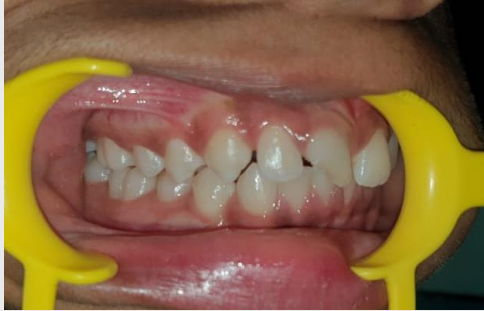ZIRCONIA CROWN IN RELATION TO 11



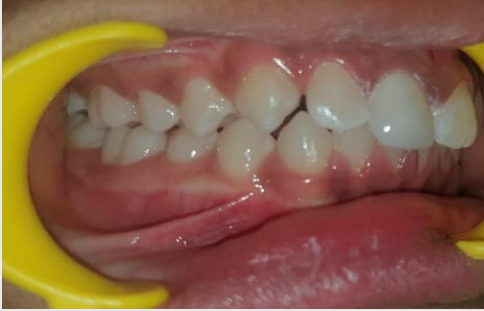PRE- OP FRONTAL



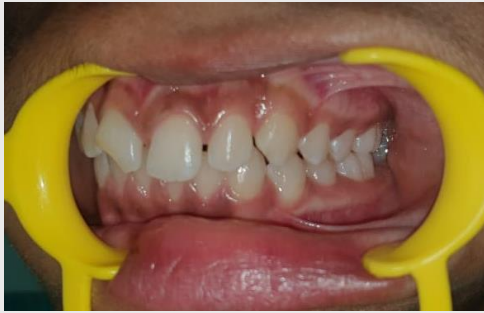POST- OP FRONTAL



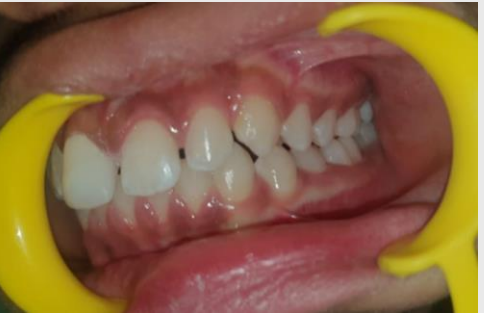PRE- OP RIGHT LATERAL



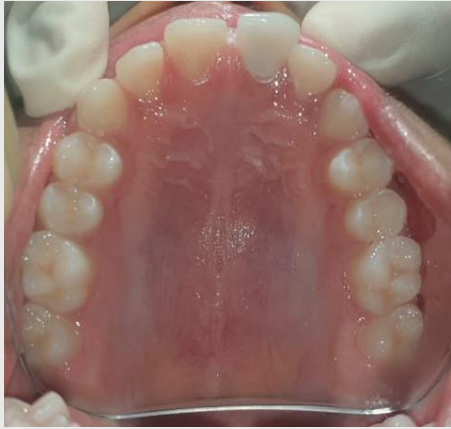POST- OP RIGHT LATERAL



PRE- OP LEFT LATERAL

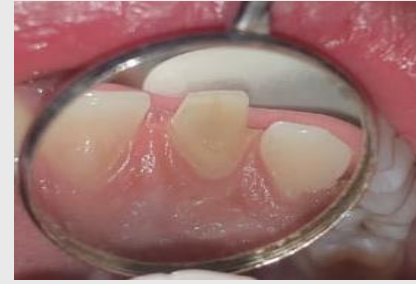
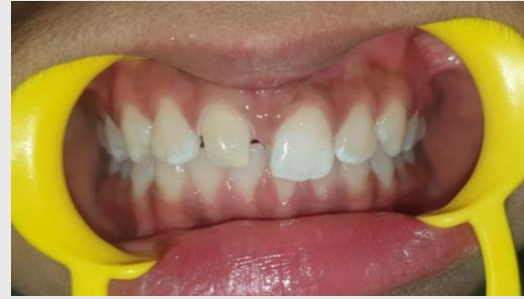
POST- OP LEFT LATERAL

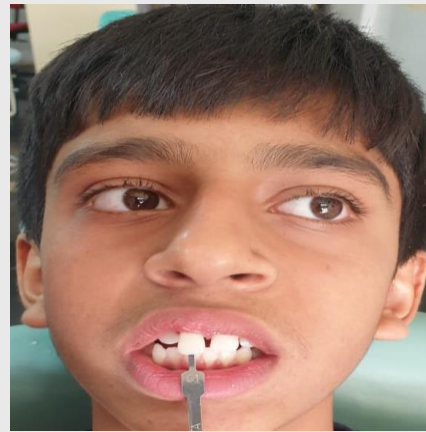

POST INSERTION

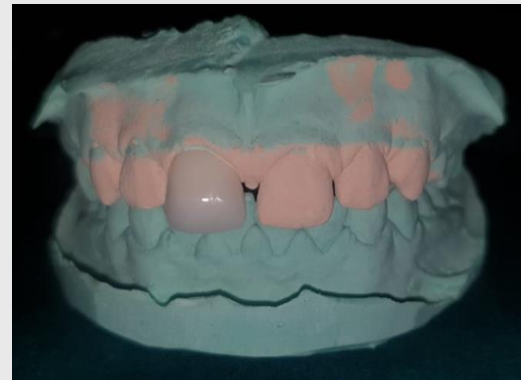TOOTH PREPARATION



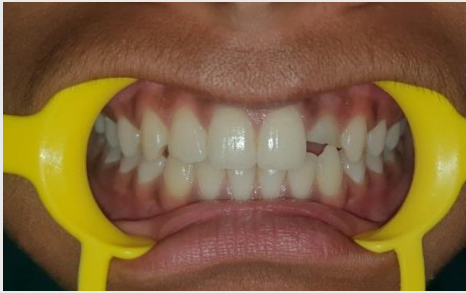SHADE SELECTION



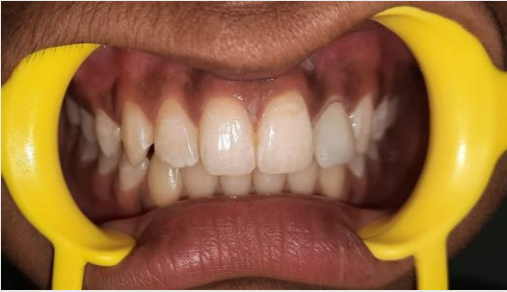FABRICATED ZIRCONIA CROWN



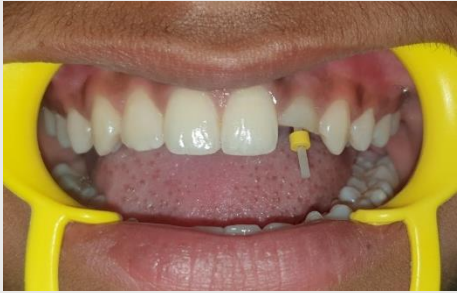POST AND CORE W.R.T 22 FOLLOWED BY ZIRCONIA CROWN



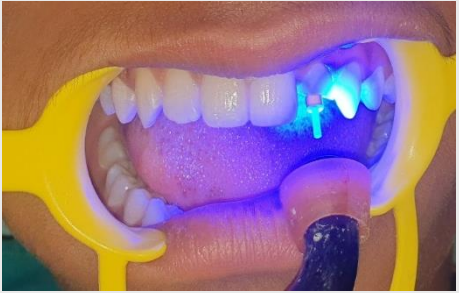PRE- OP OCCLUSAL



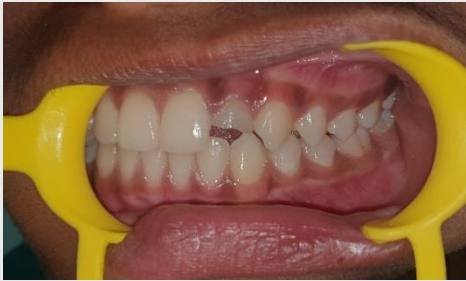POST- OP OCCLUSAL



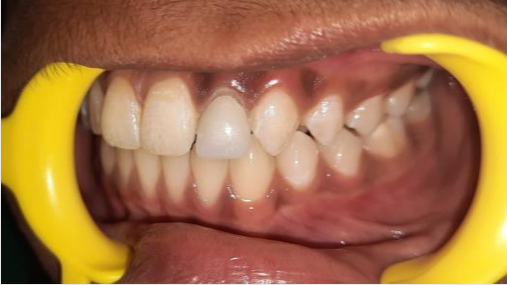FIBER POST PLACED



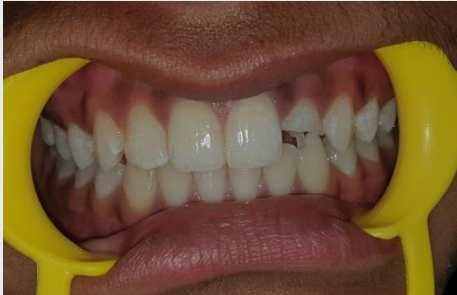LIGHT CURING



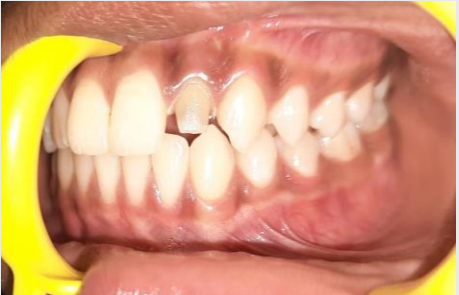PRE- OP LEFT LATERAL



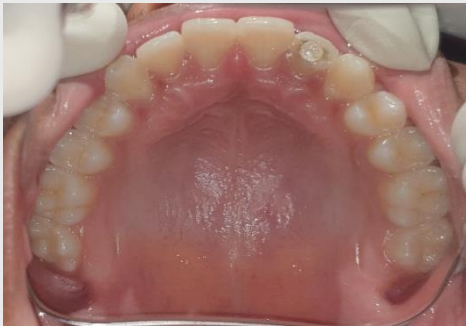POST- OP LEFT LATERAL



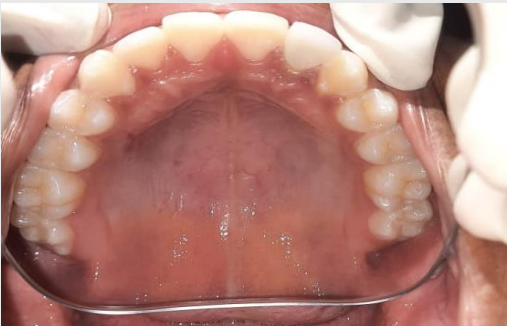CUTTING ADEQUATE LENGTH OF THE POST



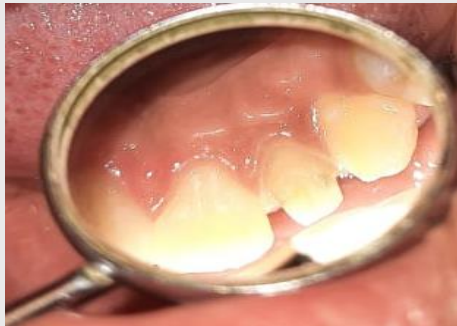
TOOTH PREPARATION- LABIAL



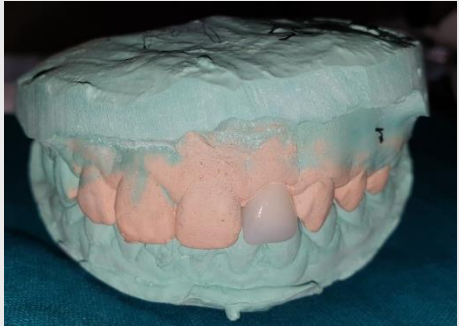PRE- OP OCCLUSAL



POST- OP OCCLUSAL

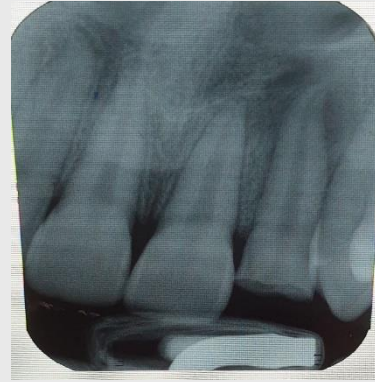

TOOTH PREPARATION- LINGUAL

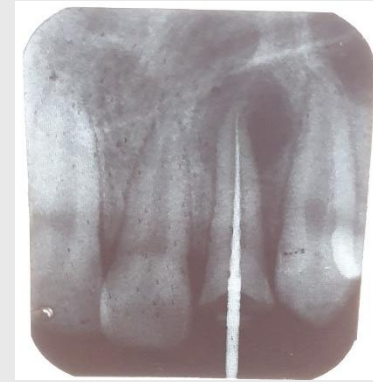

ZIRCONIA CROWN FABRICATED

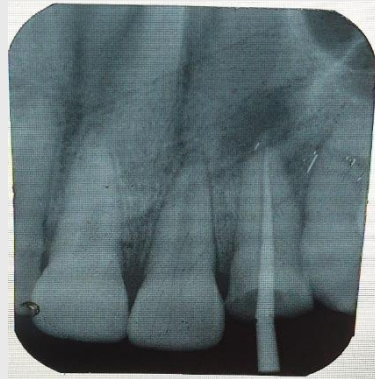RADIOGRAPHS



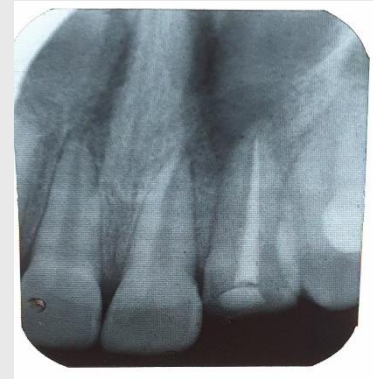PRE-OP



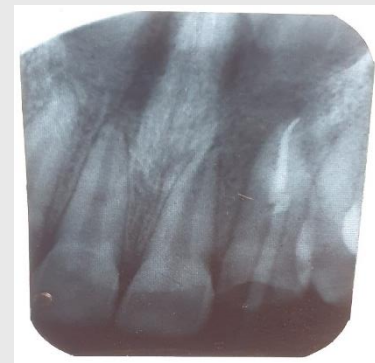
WORKING LENGTH



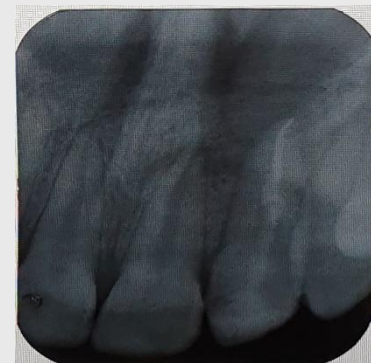MASTER CONE



GUTTA PERCHA OBTURATION

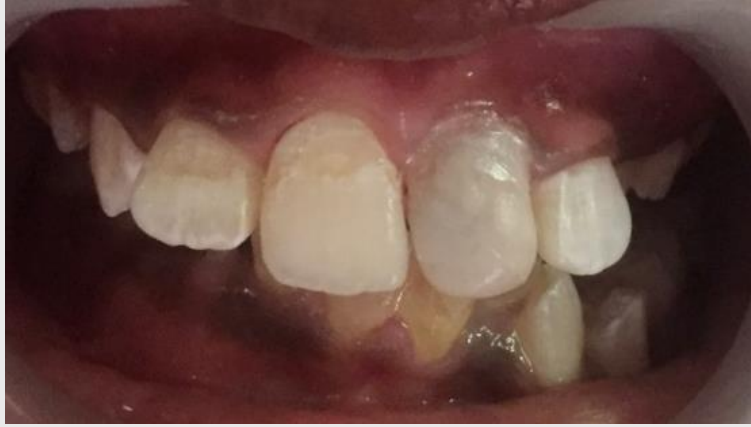

FIBER POST PLACED

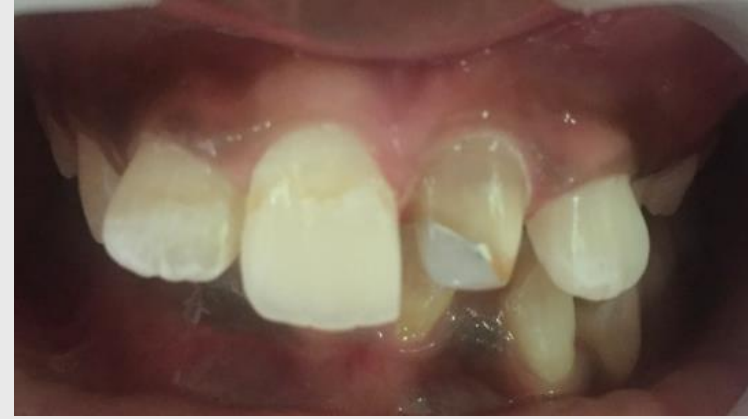

CORE BUILDUP DONE

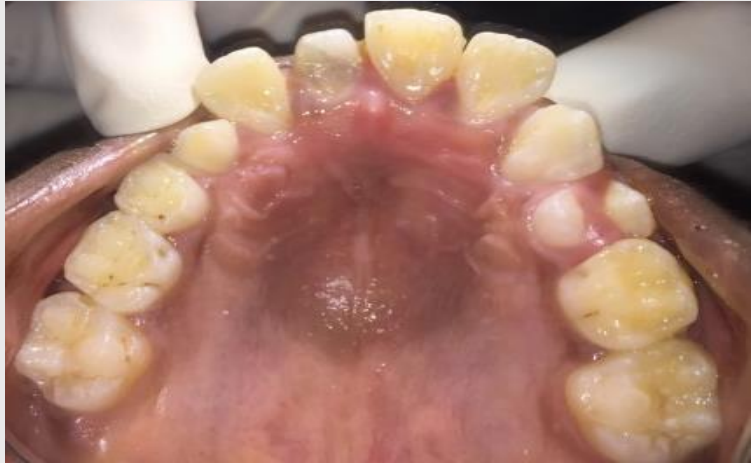ACRYLIC CROWN WRT 21



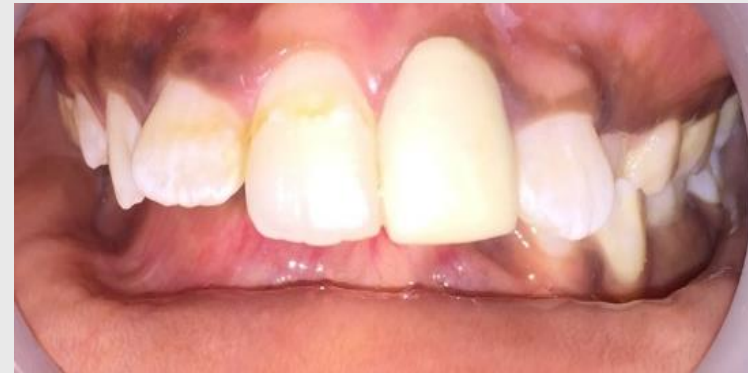Pre Op Composite build up irt 21



Tooth preparation frontal View irt 21

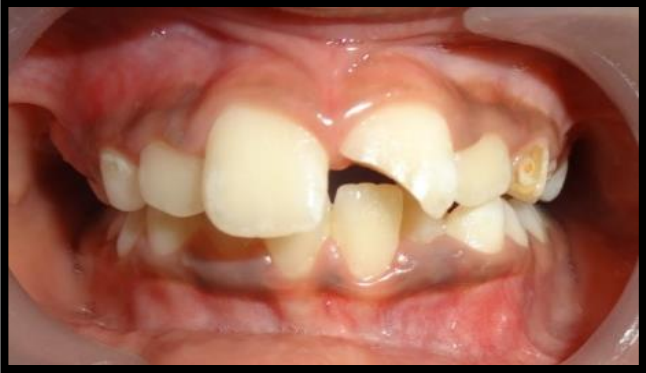

Tooth preparation palatal view irt 21

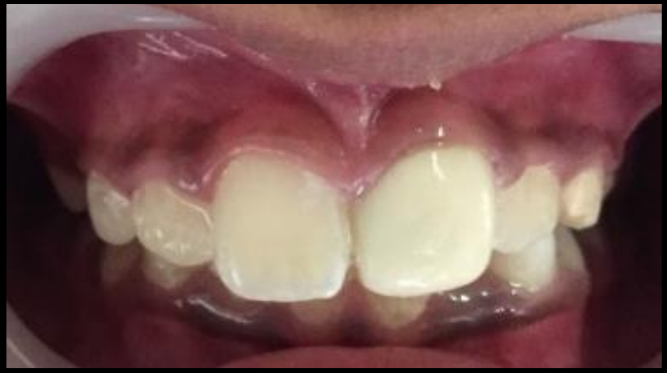

Acrylic crown irt 21

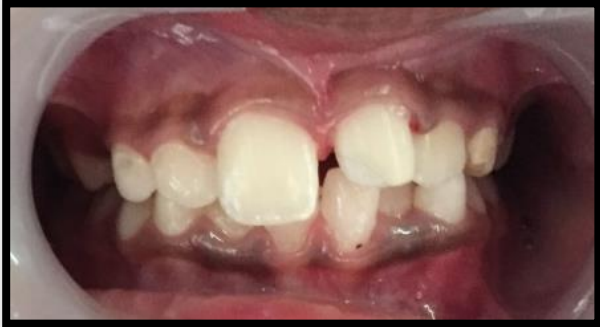Acrylic Fused Metal crown in relation to 21



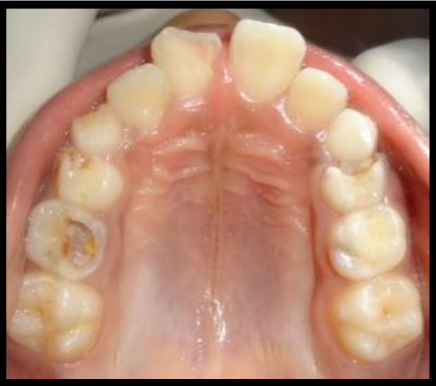Pre-Op Frontal View



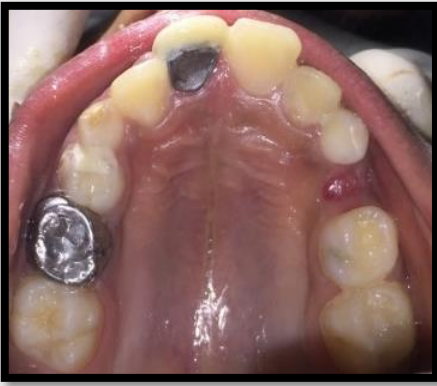Post-Op Frontal View



Tooth Preparation with 21

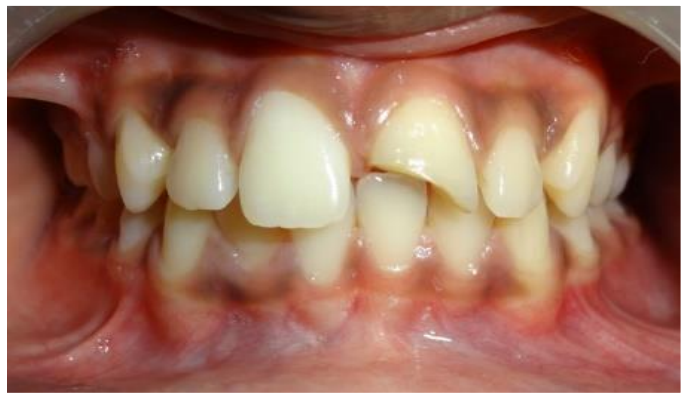

Pre-Op Occlusal View

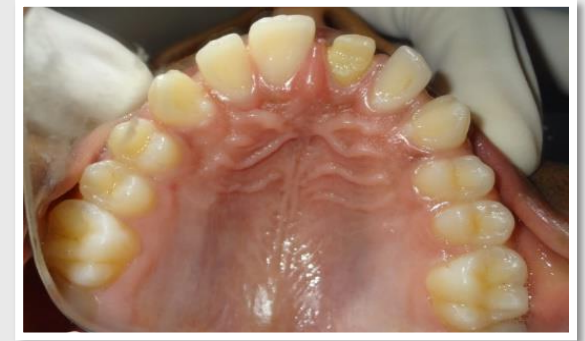
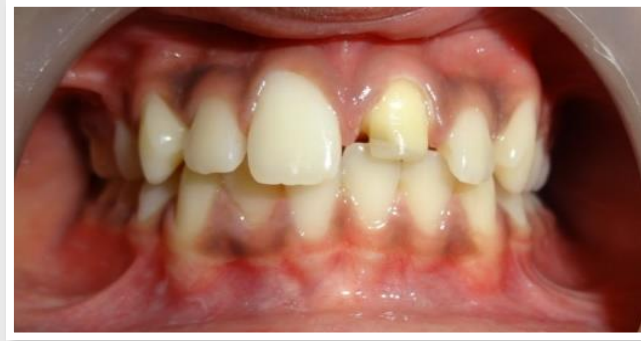
Post-Op Occlusal View

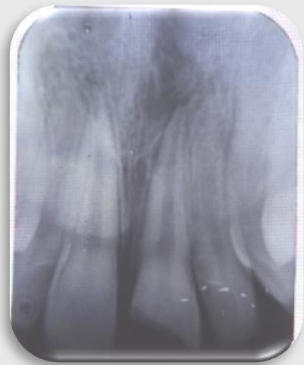Porcelain fused to metal crown i.r.t 21



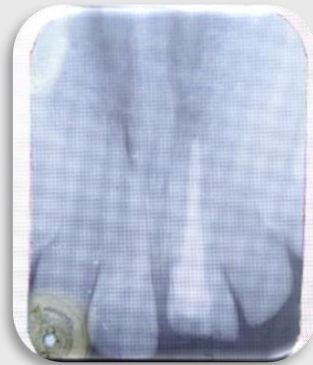Pre op – Ellis Class III # irt 21



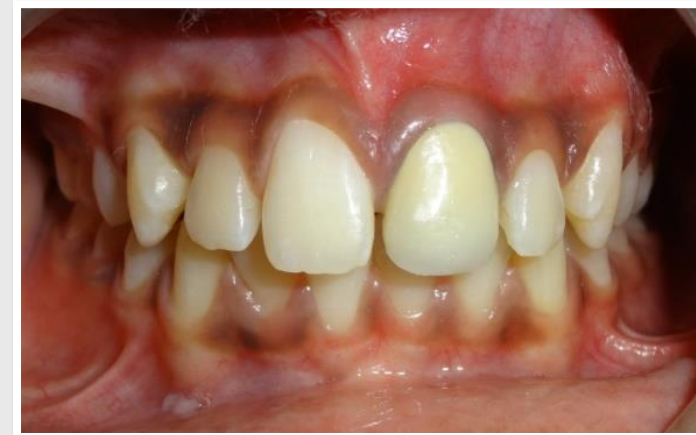Tooth preparation



Pre op IOPA

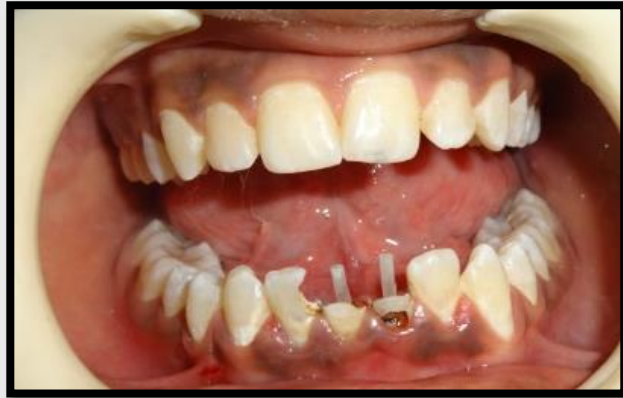

Obturation

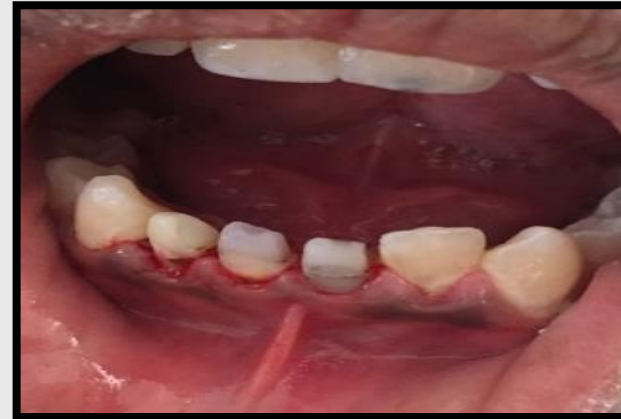

Porcelain fused to metal crown irt 21

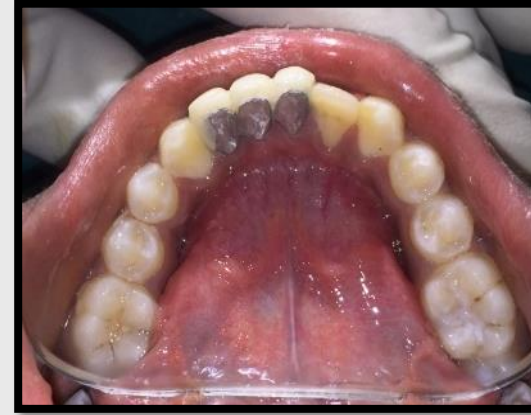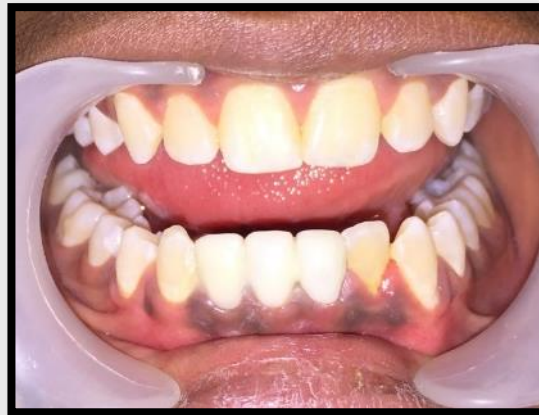Fiber Post in relation to 31 , 41,and 42



Fiber post placement



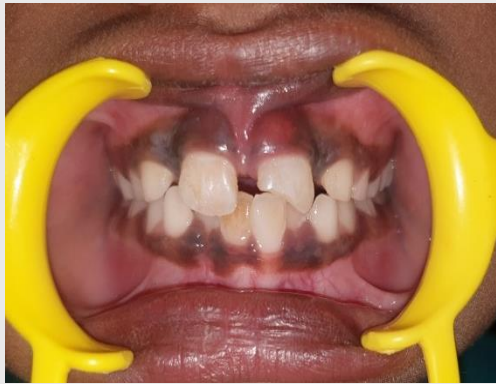Tooth preparation Occlusal view



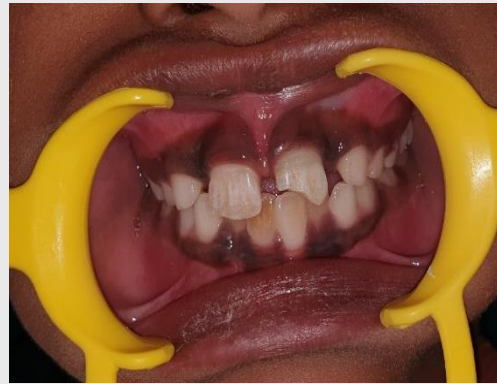PFM crowns irt 31,41 and 42

REGENERATIVE
ENDODONTICS

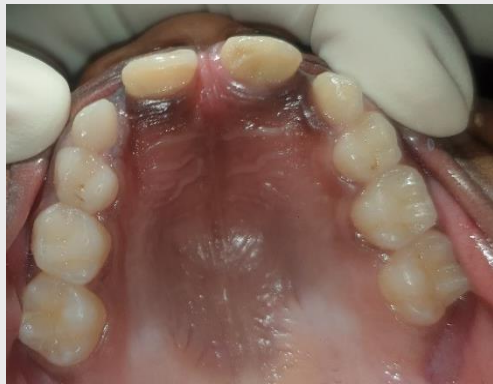Maturogenesis With Platelet Rich Fibrin [PRF] On 21



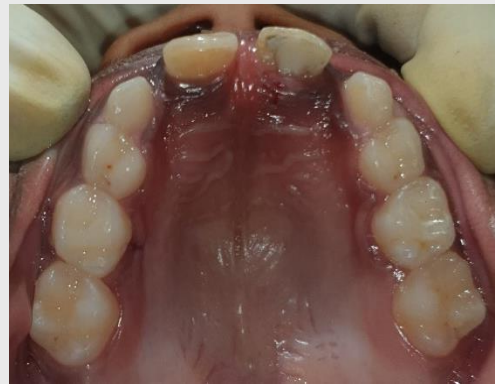PRE-OPERATIVE- LABIAL VIEW



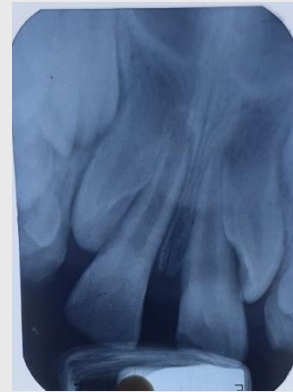
POST-OPERATIVE- LABIAL VIEW



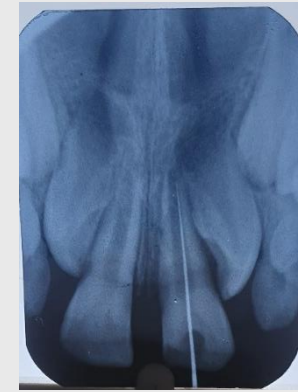PRE-OPERATIVE OCCLUSAL VIEW



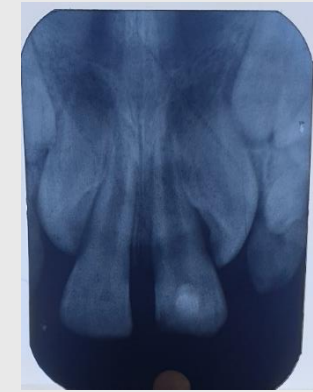
POST-OPERATIVE- LINGUAL VIEW



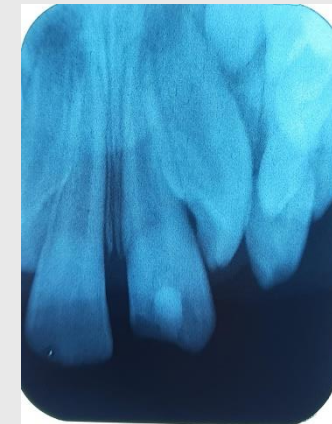
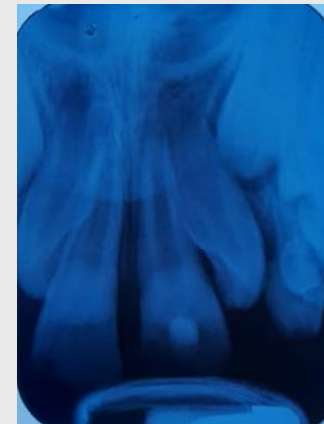PRE- OPERATIVE

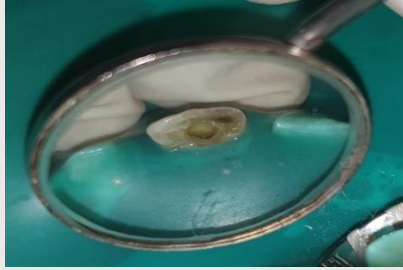

WORKING LENGTH

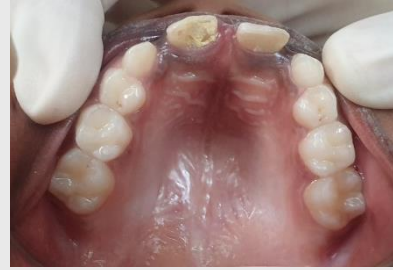

IMMEDIATE
POST- OPERATIVE



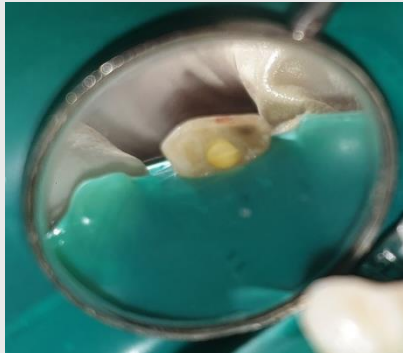

ACCESS OPENING,
PULP EXTIRPATION

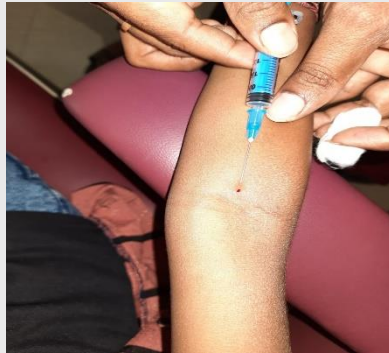

TRIPLE ANTIBIOTIC CLOSED
DRESSING GIVEN FOR 15 DAYS

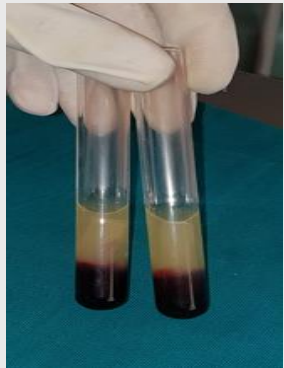
AFTER 15 DAYS - ON DAY OF PROCEDURE



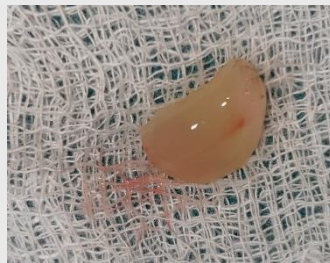CANAL REASSESSED AND CLEANED



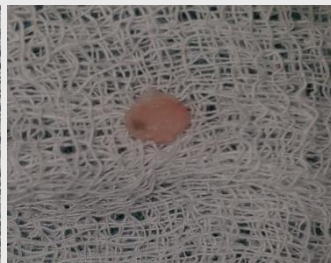BLOOD COLLECTION



BLOOD AFTER
CENTRIFUGATION

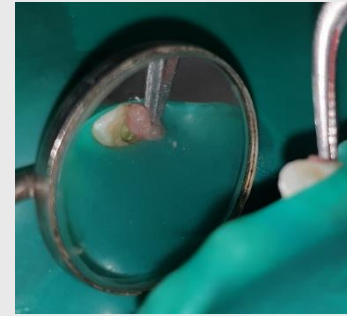


PRF Clot

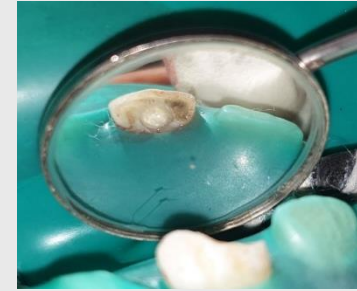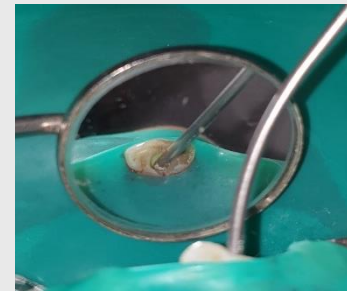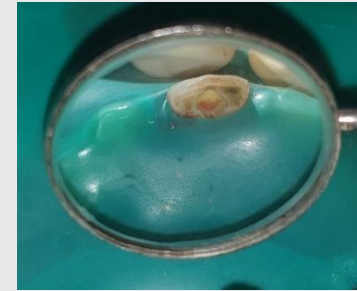
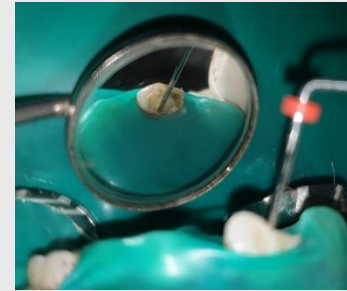


PRF SQUEEZED TO
FORM A
MEMBRANE

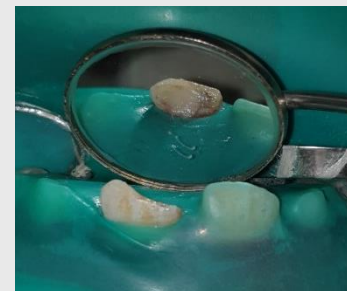P
R
O
C
E
D
U
R
E



PRF PLACEMENT IN PULP CANAL

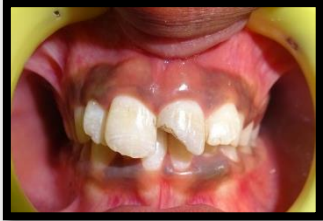

BIODENTINE
PLACEMENT

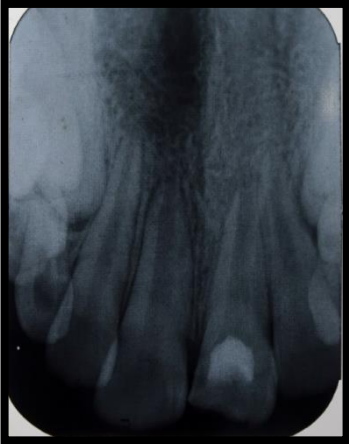

GIC PLACED

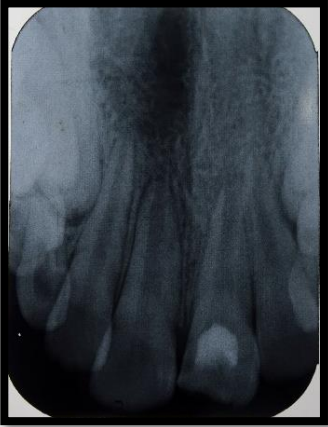APEXOGENESIS WITH PRF



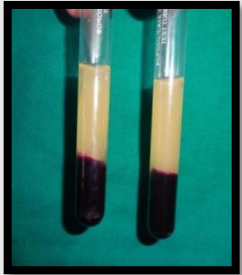PRE OP



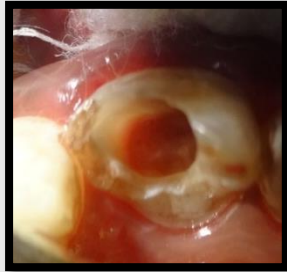1 MONTH



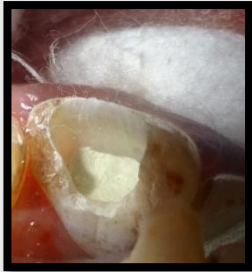3 MONTHS



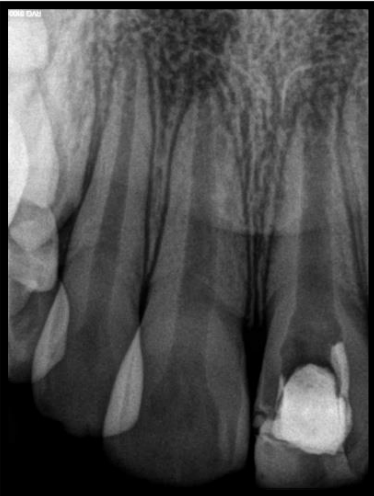PRF



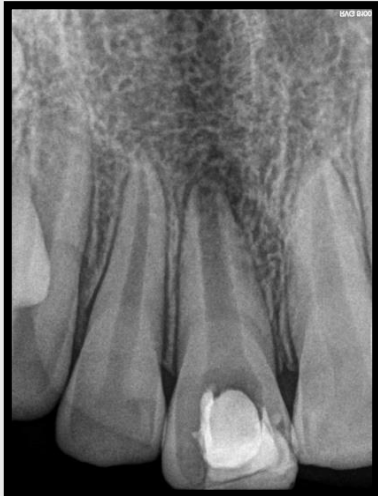PRF PLACED
IN CANAL



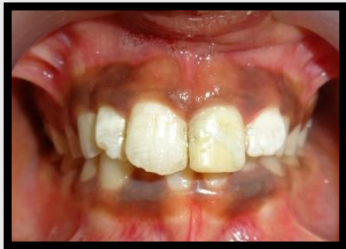MTA BARRIER
PLACED



6 MONTHS

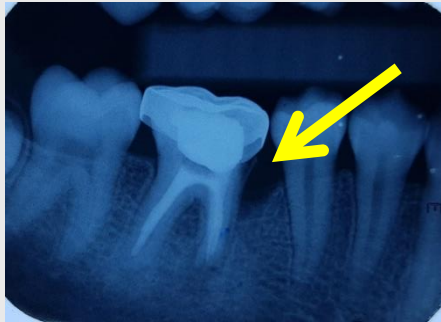
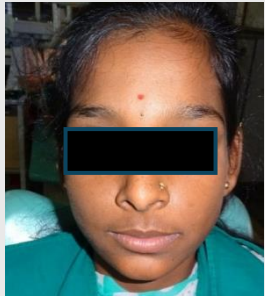

9 MONTHS

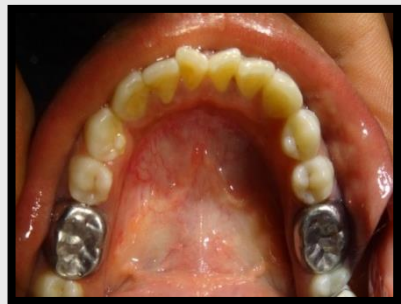

POST OP

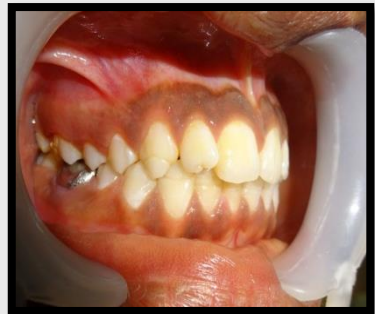TREATMENT OF VERTICAL BONY DEFECT WITH PRF



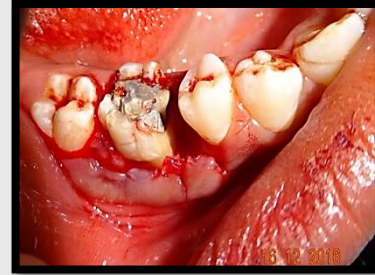PRE OP IOPA



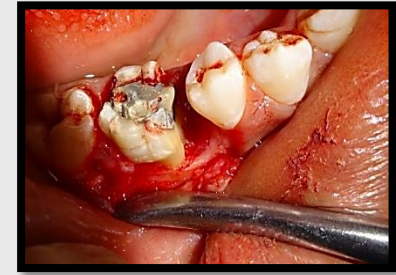PREOP MANDIBLE



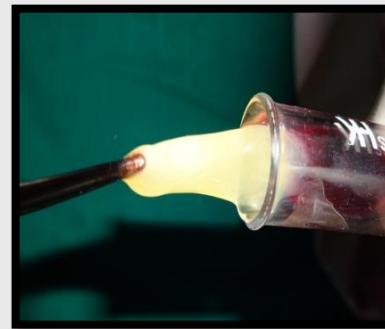
LATERAL VIEW



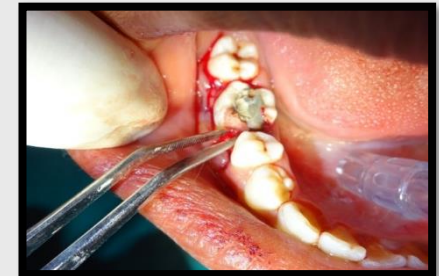INCISIONS PLACED



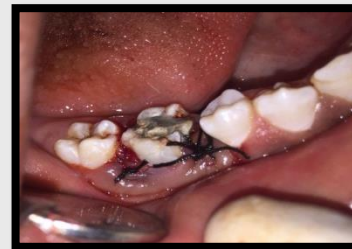FLAP RAISED



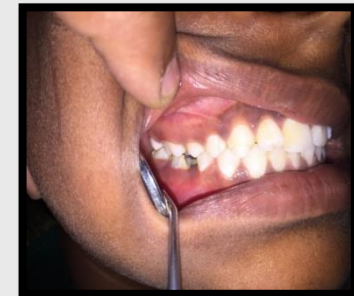PRF



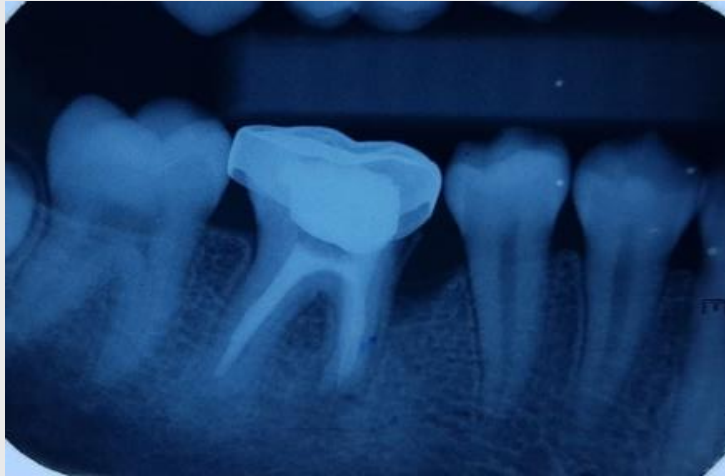
PRF PLACED



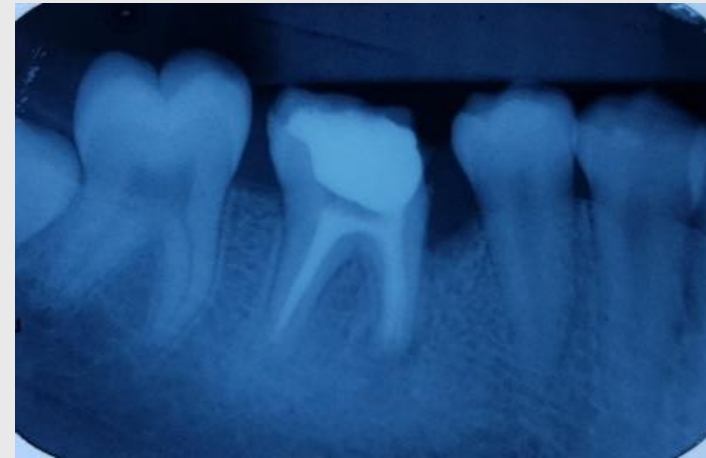SUTURES PLACED



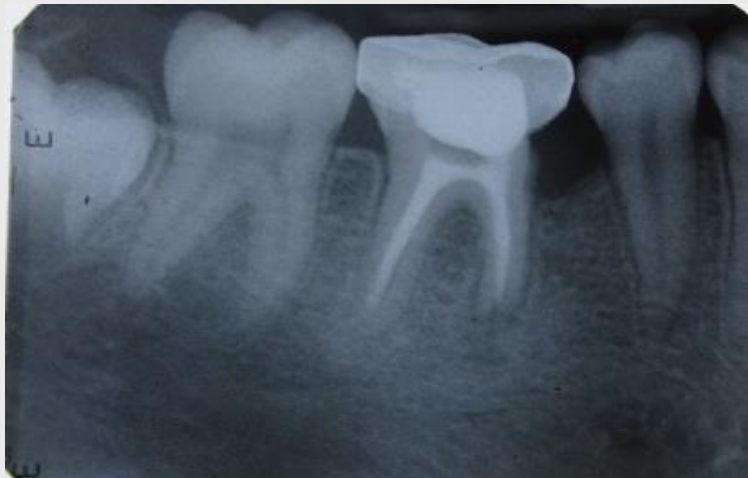1 MONTH POST OP



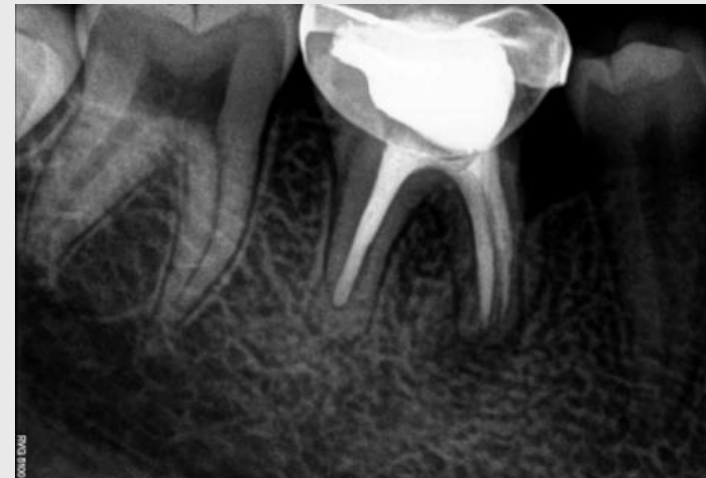PRE OP



IMMEDIATE POST OP

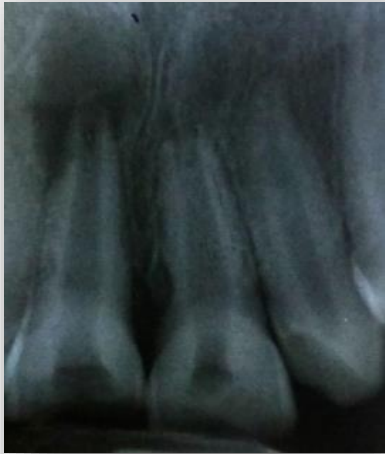

3 MONTHS

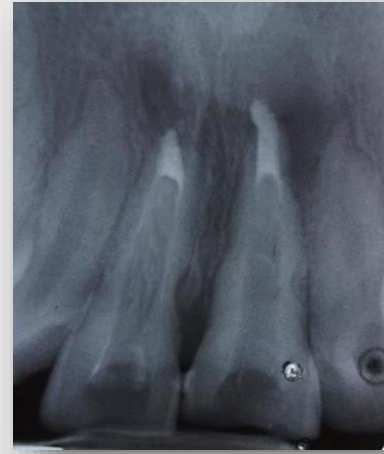
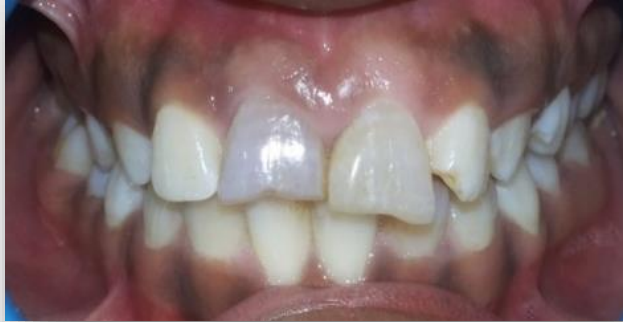
6 MONTHS

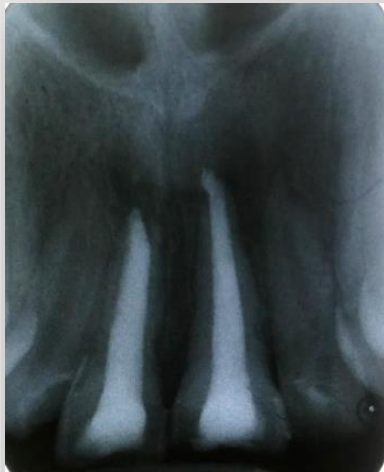MTA APEXIFICATION



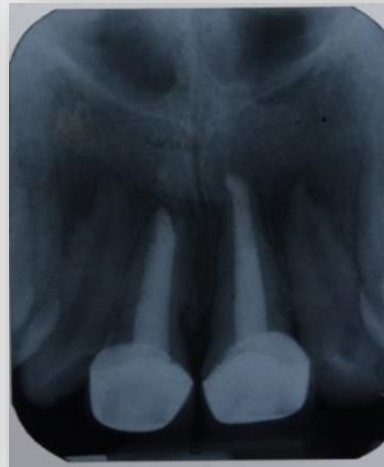PREOP



MTA PLACEMENT



POST OP - IOPA

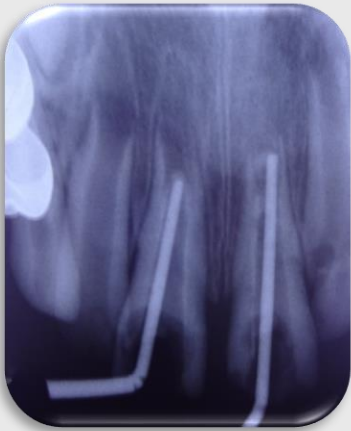

3 MONTHS FOLLOW UP

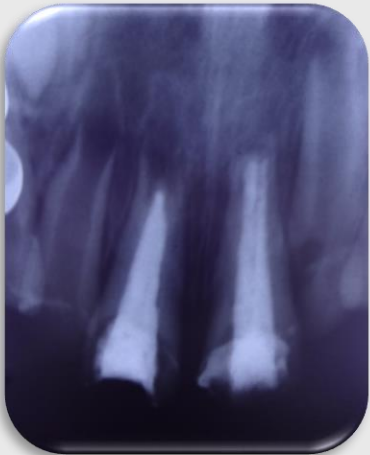BIODENTIN APEXIFICATION



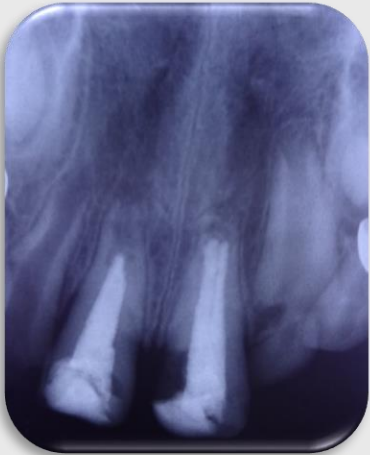Pre op



Working length

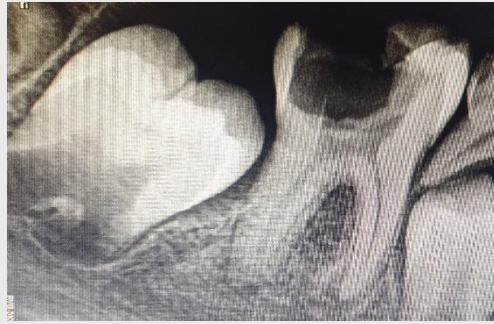

Biodentin apexification

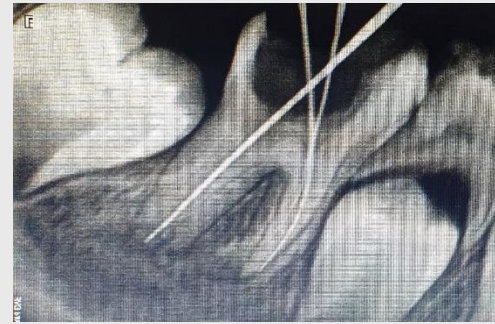

6 month follow up

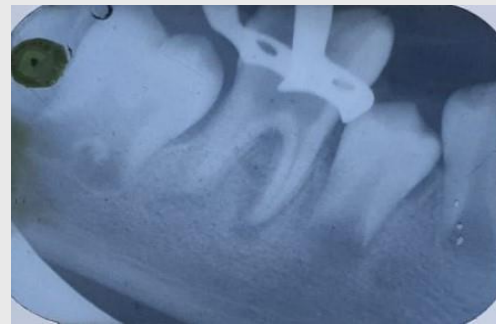APEXIFICATION USING BIODENTINE IN PERMANENT POSTERIOR TEETH



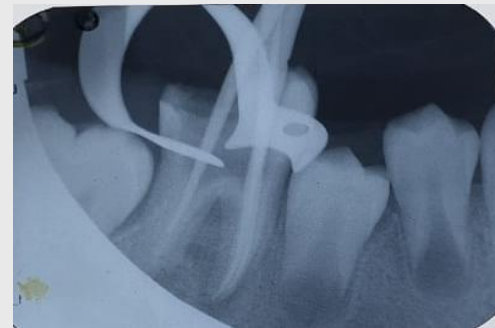PRE- OPERATIVE



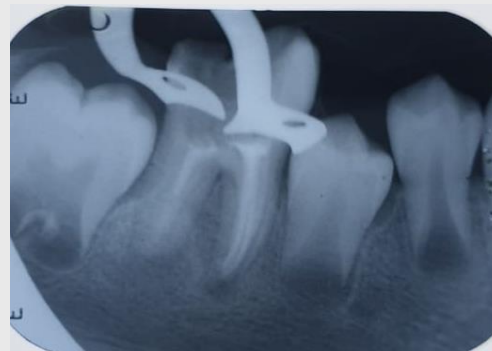WORKING LENGTH



BIODENTINE PLUG (4MM) IN
DISTAL CANAL

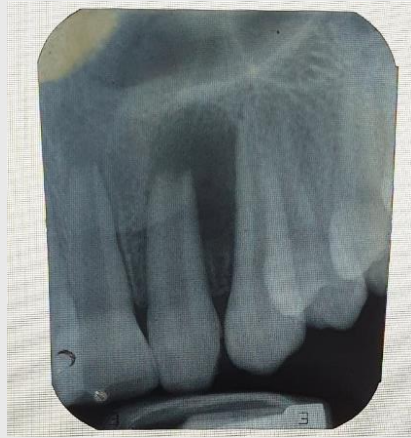

MASTER CONE RADIOGRAPH

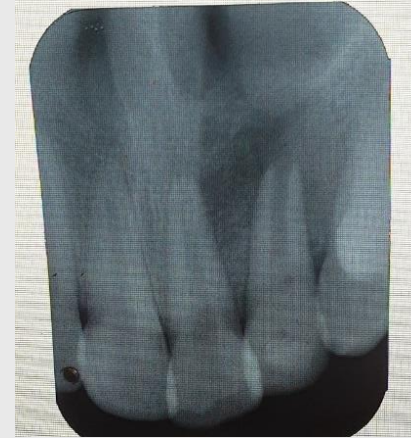

OBTURATION WRT 46

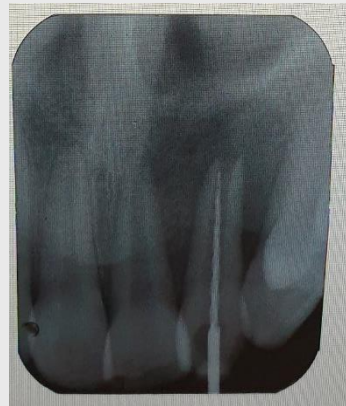APEXIFICATION USING BIODENTINE IN PERMANENT ANTERIOR TEETH



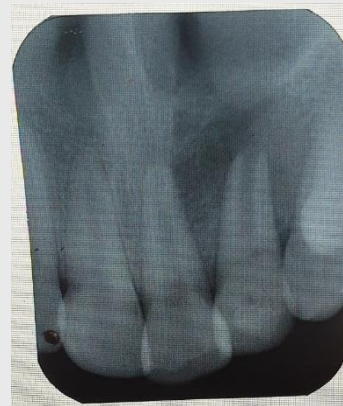PRE-OP



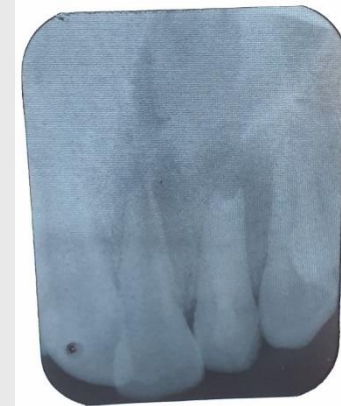AFTER 15 DAYS OF PLACING CALCIUM HYDROXIDE



WORKING LENGTH



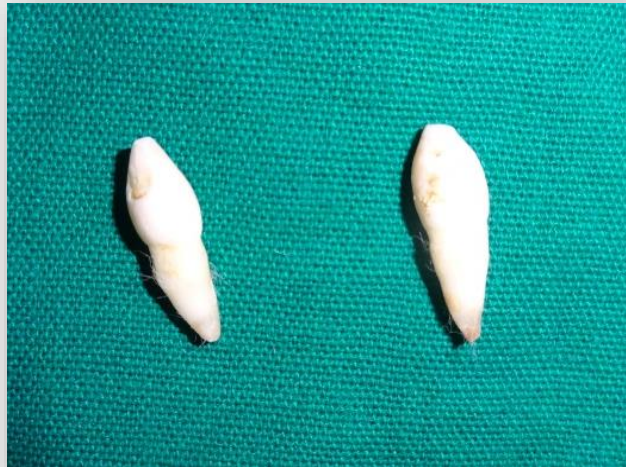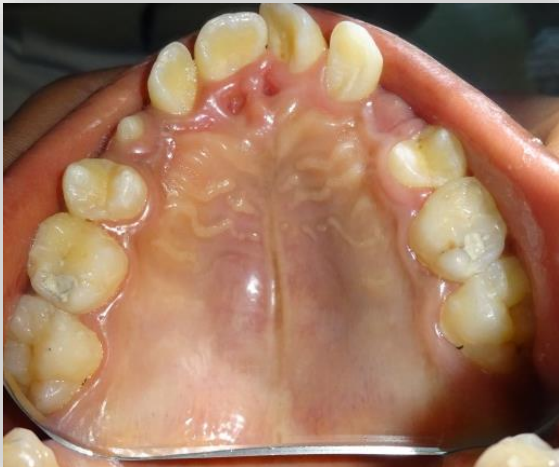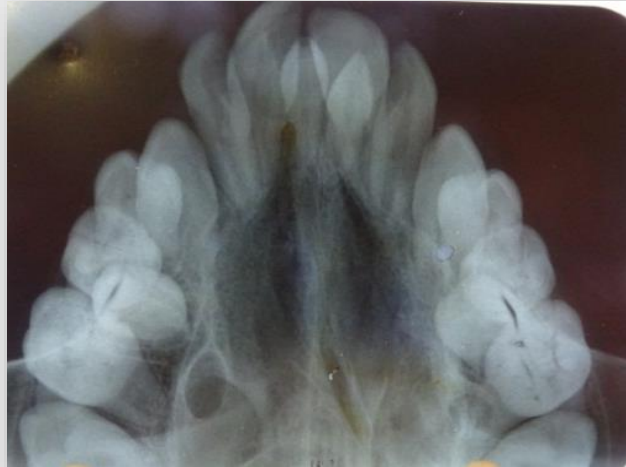
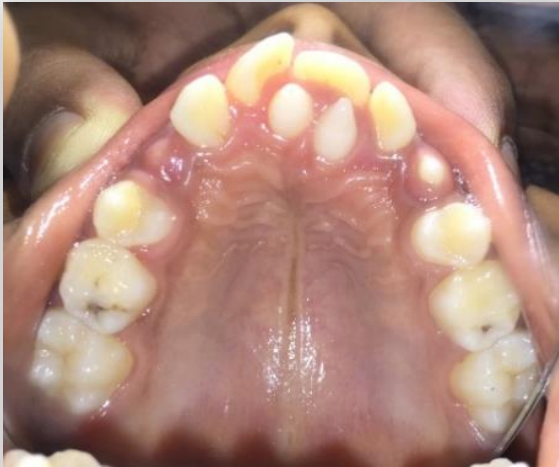BIODENTINE PLUG FORMATION



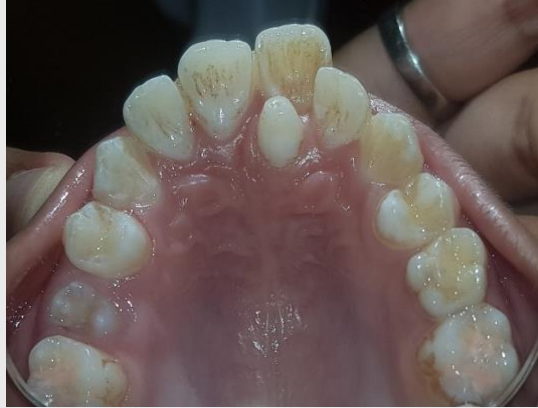OBTURATION WRT 22

MINOR SURGICAL PROCEDURE

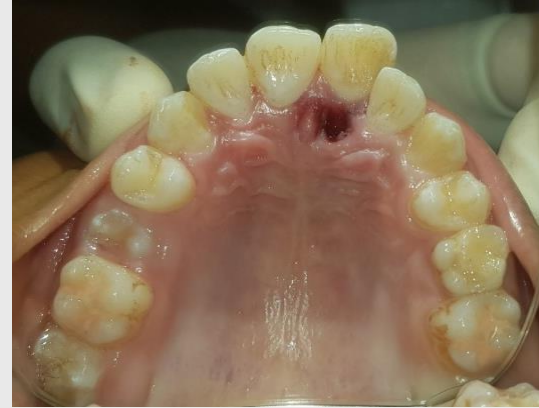Double Mesiodens



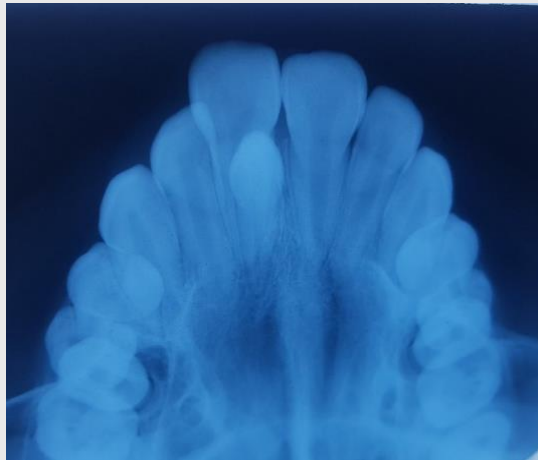
MESIODENS



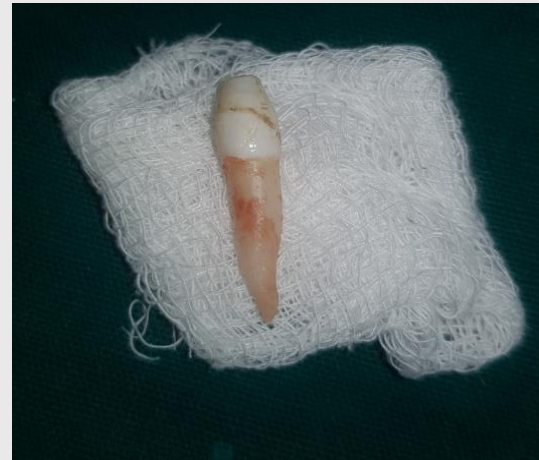PRE OP VIEW



POST OP VIEW

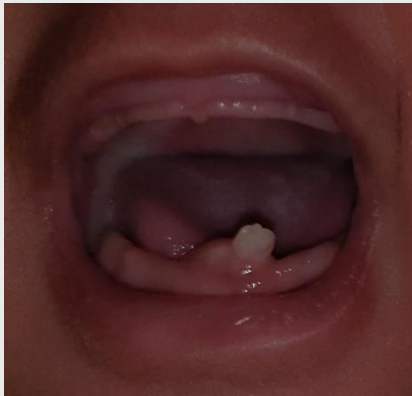

PRE OP OCCLUSAL RADIOGRAPH

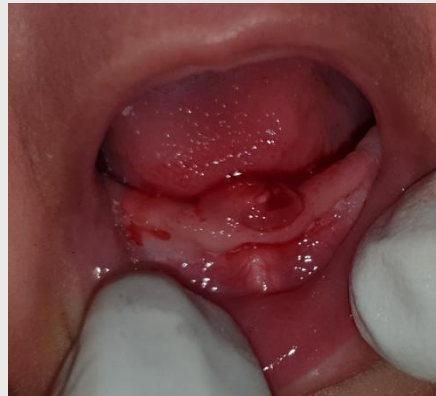

EXTRACTED MESIODENS

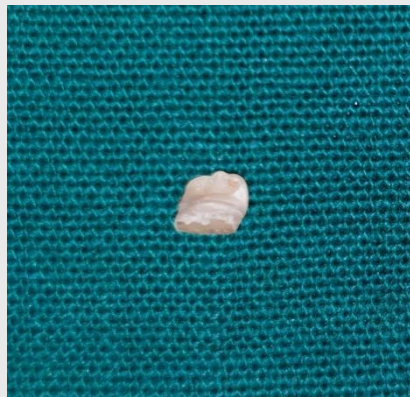NEO-NATAL TEETH



PRE OP VIEW

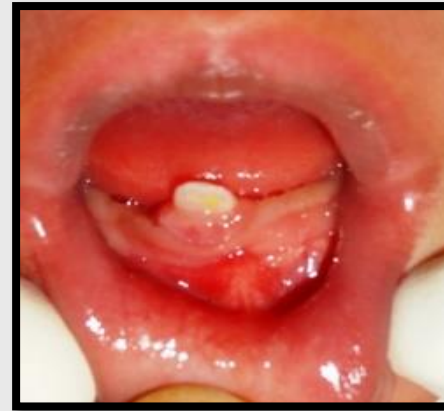

POST OP VIEW

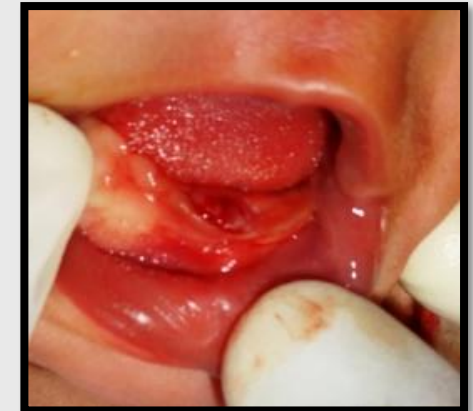

EXTRACTED TOOTH

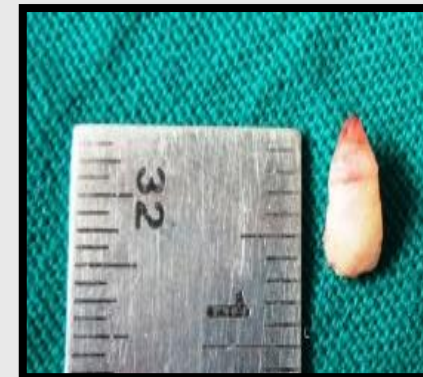NATAL TOOTH



PRE OP VIEW

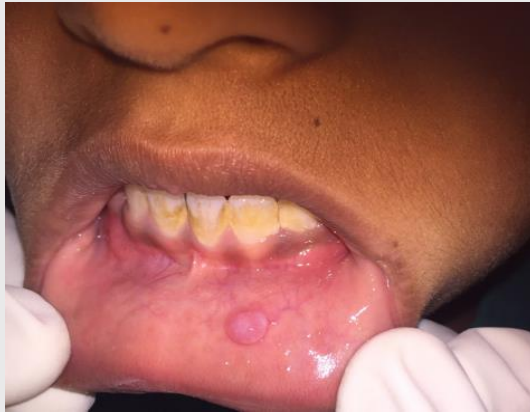

POST OP VIEW

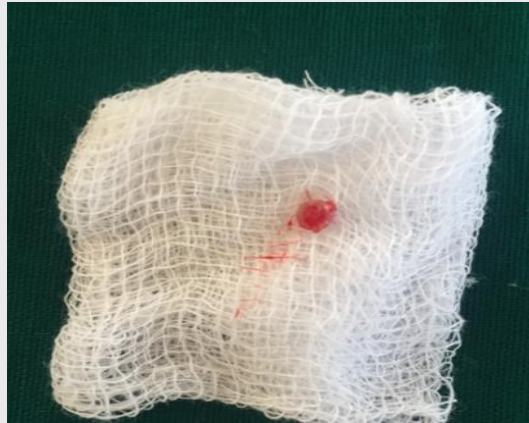

EXTRACTED TOOTH

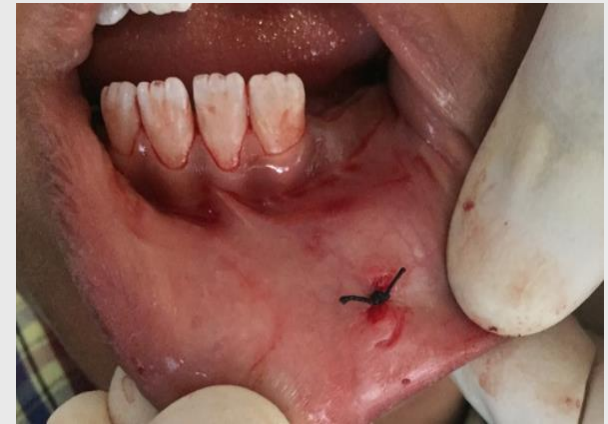MUCOCELE EXCISION: CASE 1



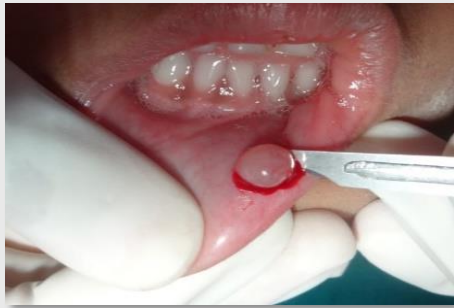Pre op – Mucocele on lower lip



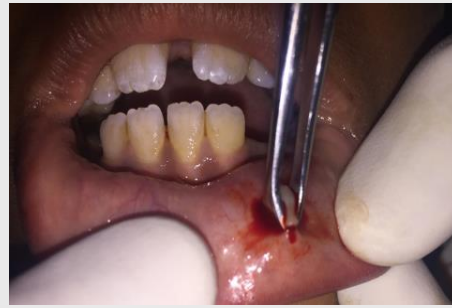Excised Mucocele on lower lip



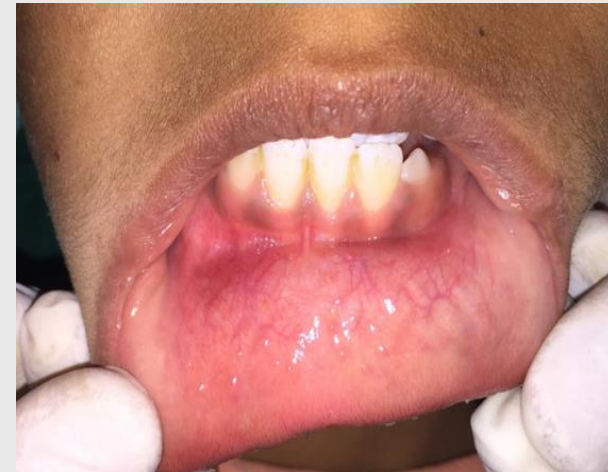Suture placed following excision of mucocele on lower lip



Placing the incision

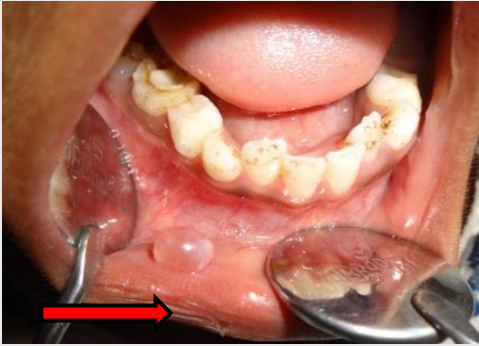

Excision of mucocele and minor salivary glands

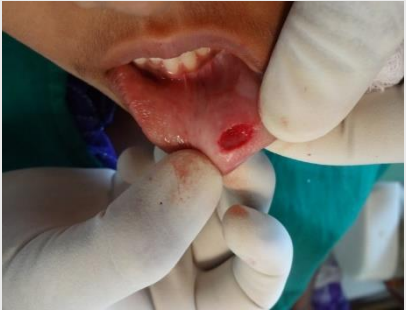

At 3 months follow up

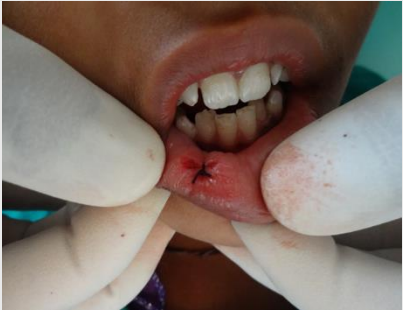MUCOCELE EXCISION: CASE 2



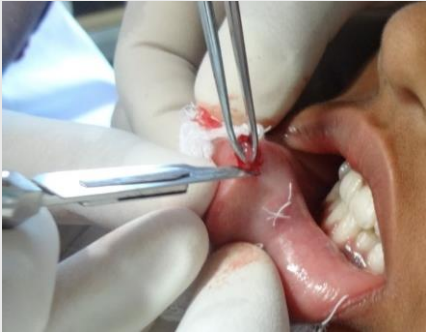Pre op – Mucocele on lower lip



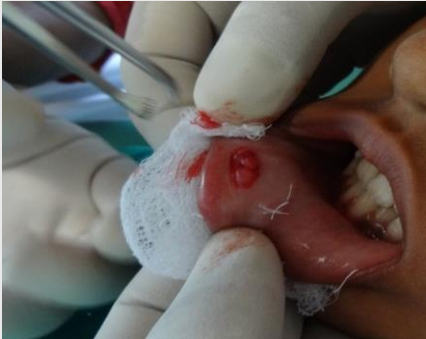Immediate post op



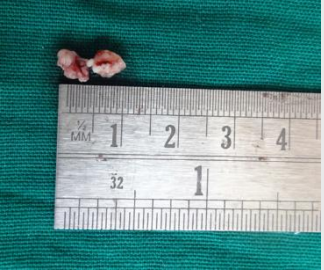Suturing



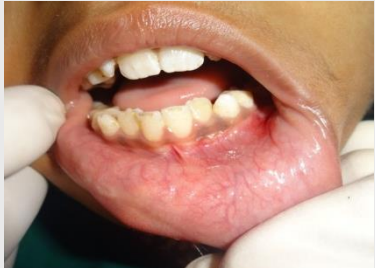Placing the incision



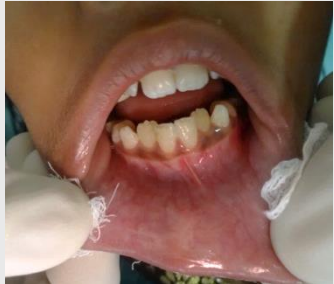Excision of mucocele and minor salivary glands



Excised mucocele

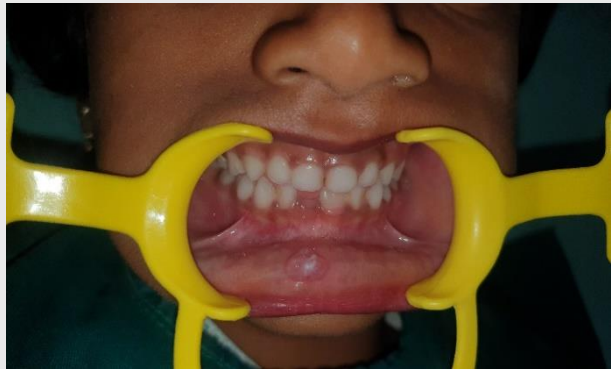

15 days follow up

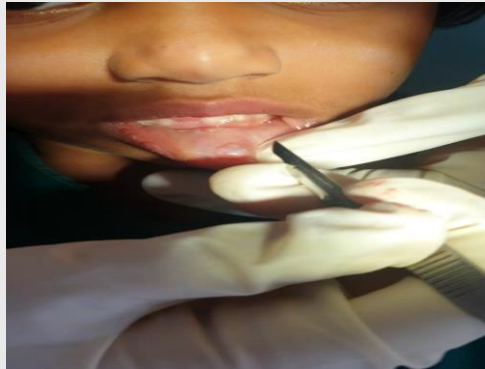

3 month follow up

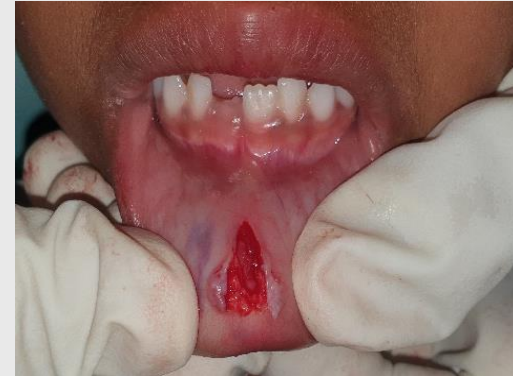SURGICAL EXCISION OF MUCOCELE: CASE 3



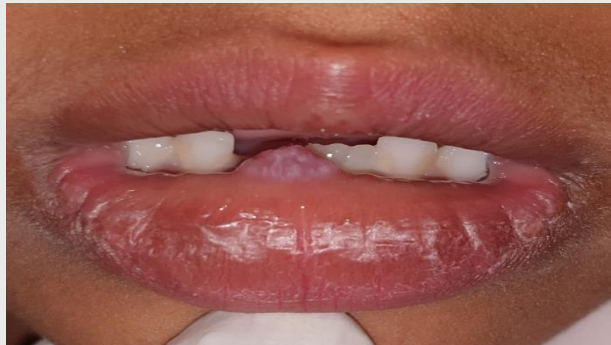PRE OP



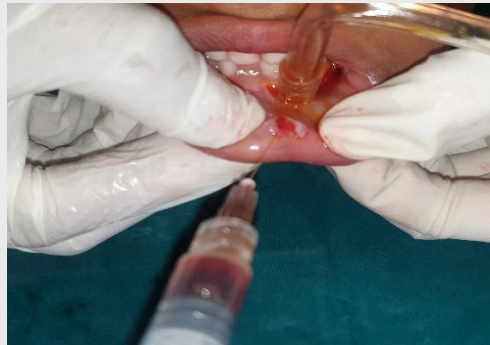INCISION



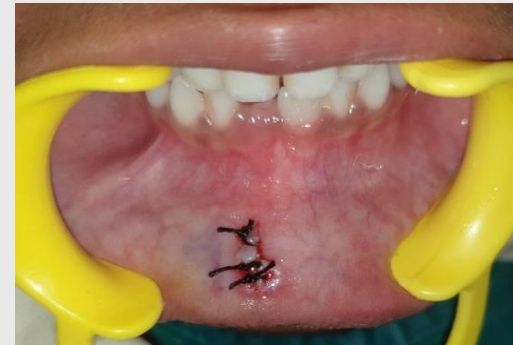EXCISING MUCOCELE



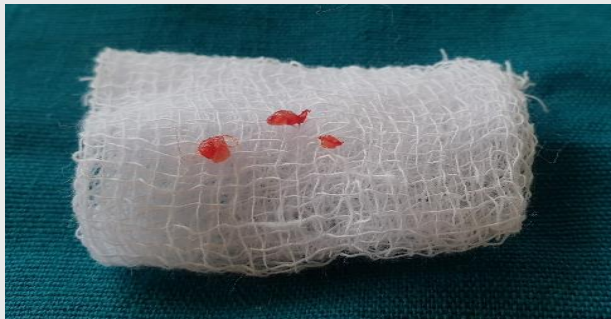PRE OP VIEW



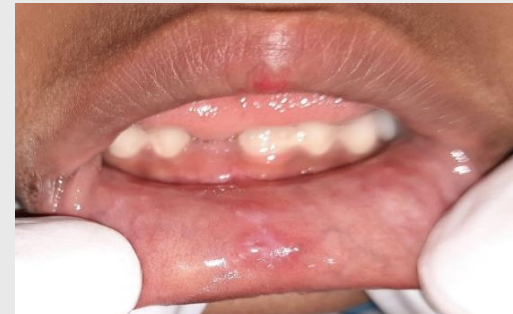BETADINE IRRIGATION



IMMEDIATE POST-OPERATIVE

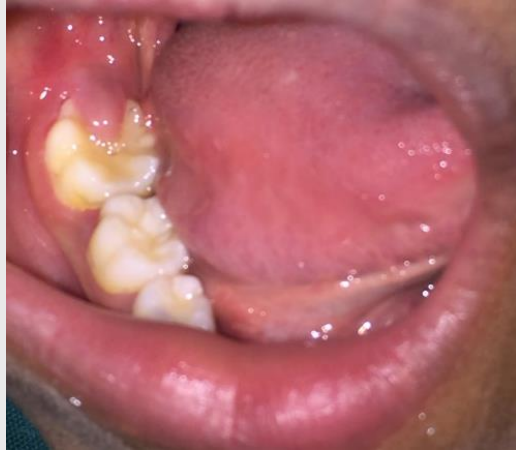

EXCISED MUCOCELE

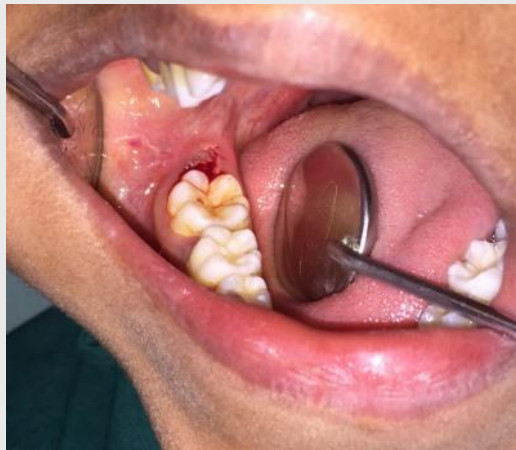
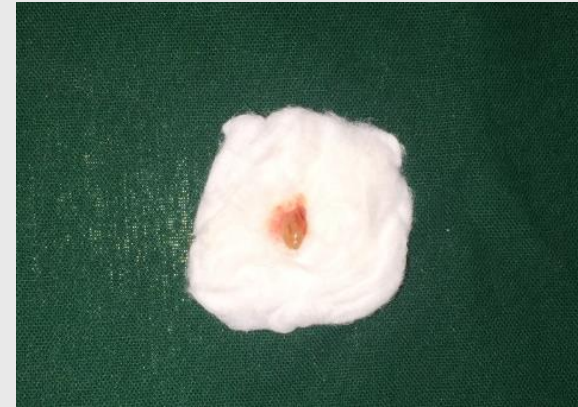
FOLLOW UP

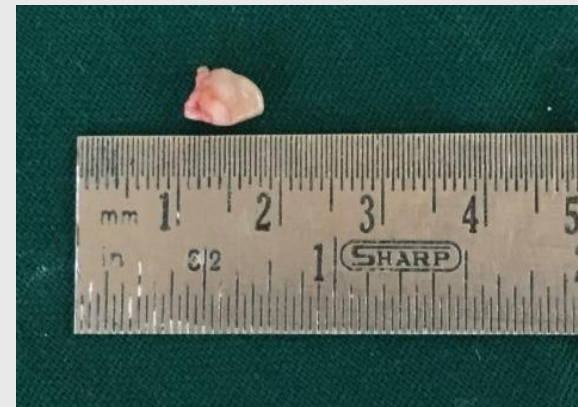PERICORONAL FLAP EXCISION



Inflamed pericoronal flap irt 46

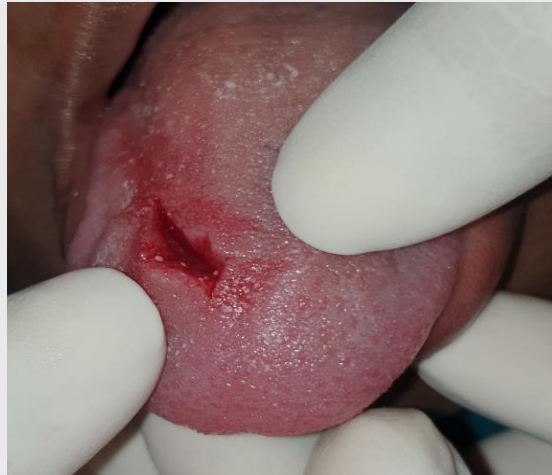

Hemostasis achieved following excision of flap

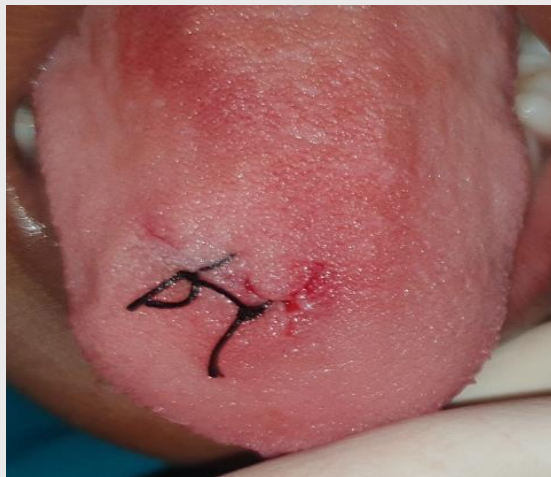

Surgically excised pericoronal flap

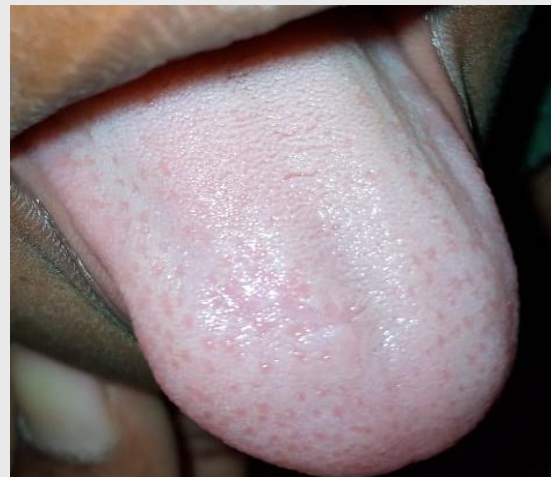TONGUE LACERATION INJURY



PRE-OPERATIVE

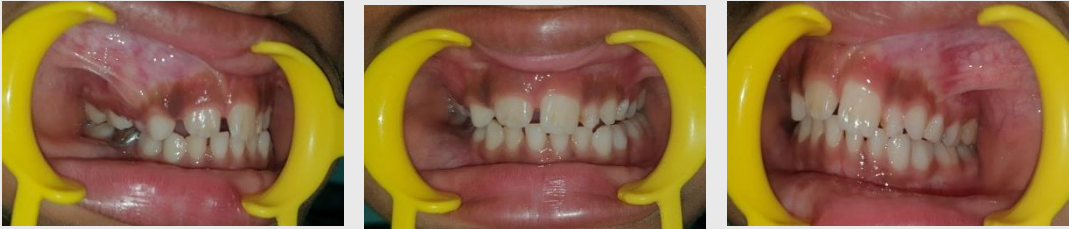

POST OPERATIVE

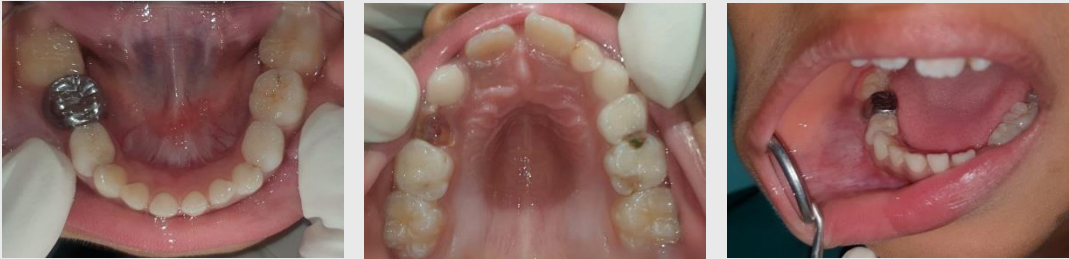

FOLLOW UP

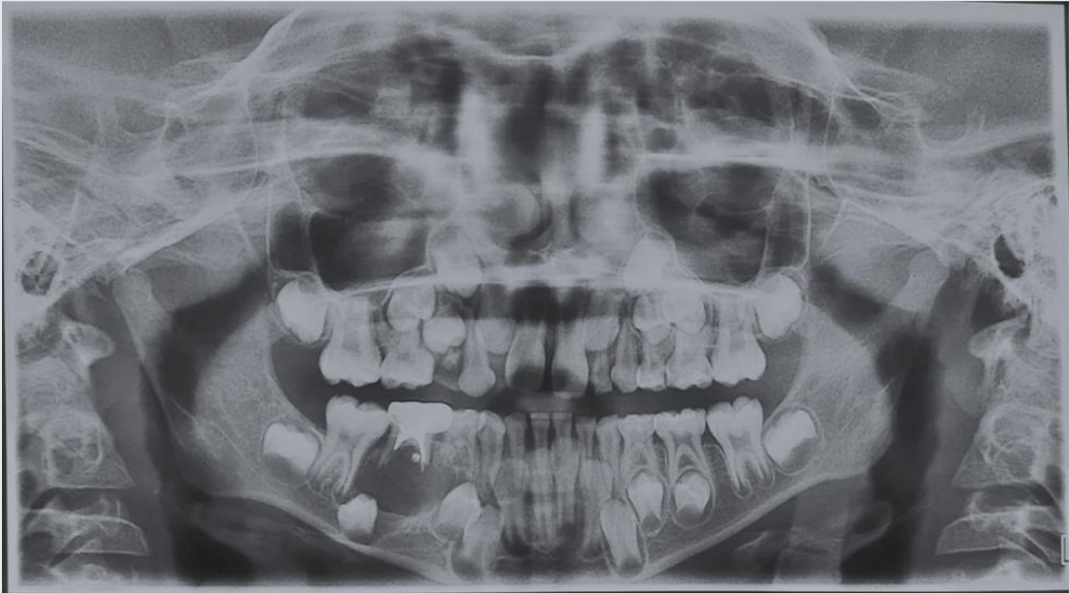RADICULAR CYST



PRE – OPERATIVE

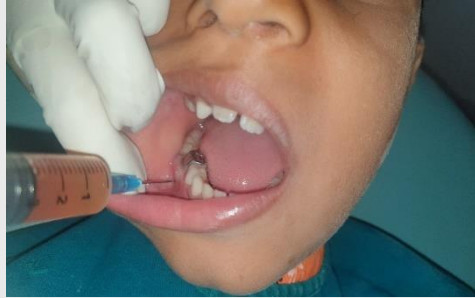

PRE – OPERATIVE OPG

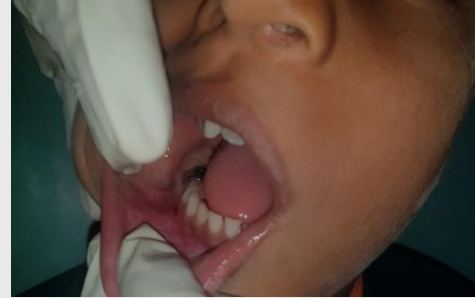

Procedure

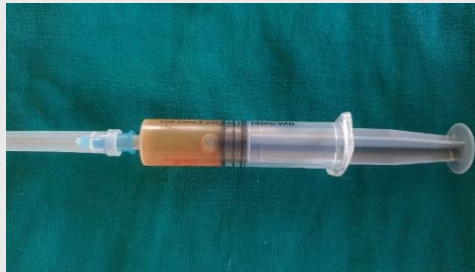Follow Up



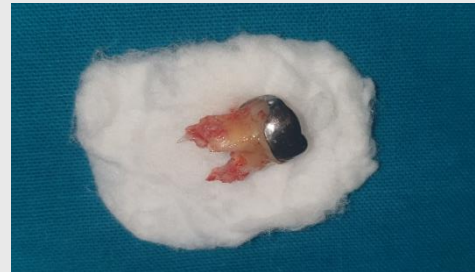Fluid Aspiration



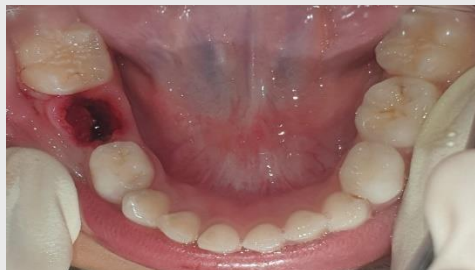Post aspiration site



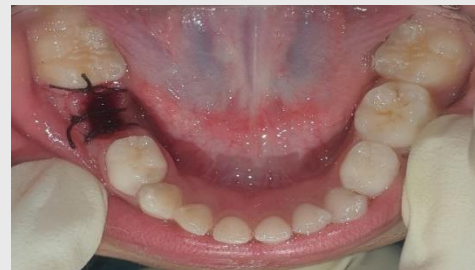Aspirated Fluid



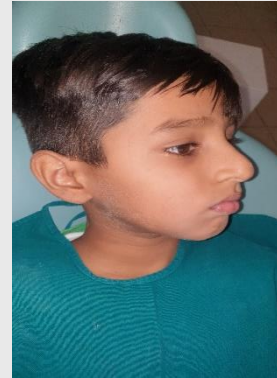Extracted Tooth



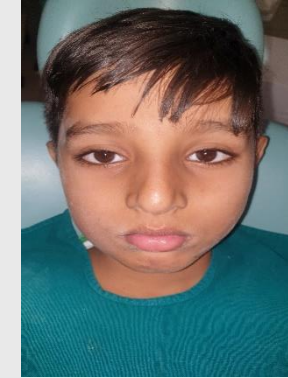
After Curretage and irrigation



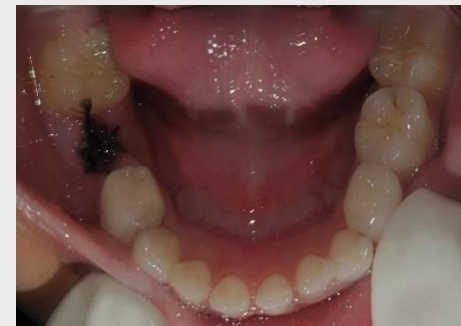Immediate Post-Operative



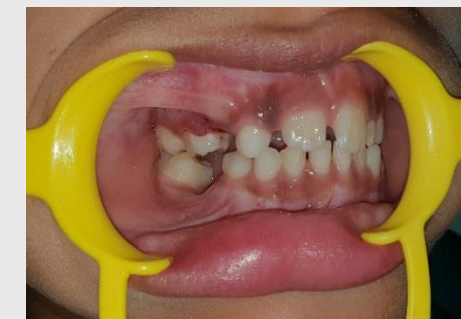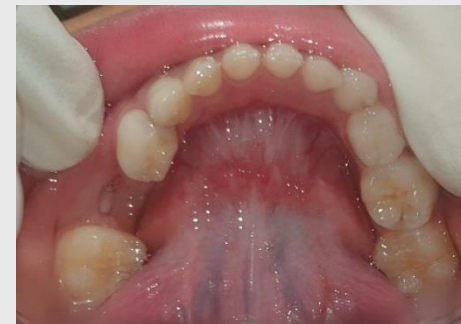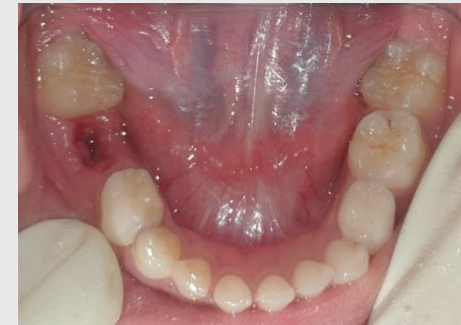7 Days



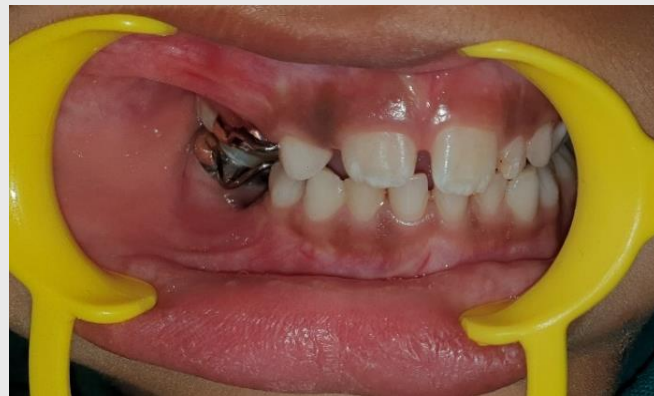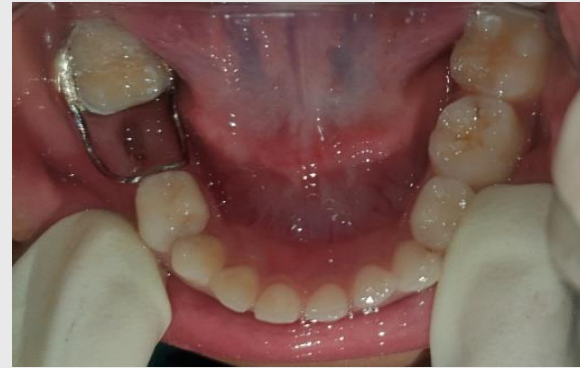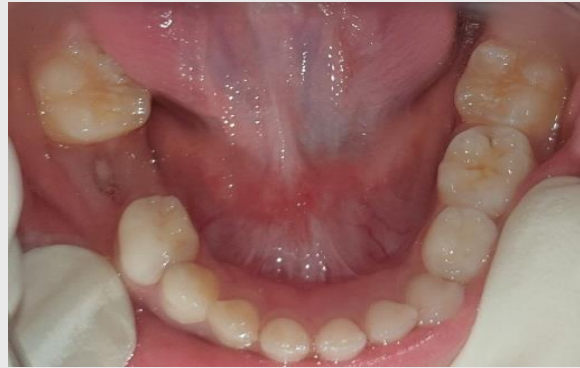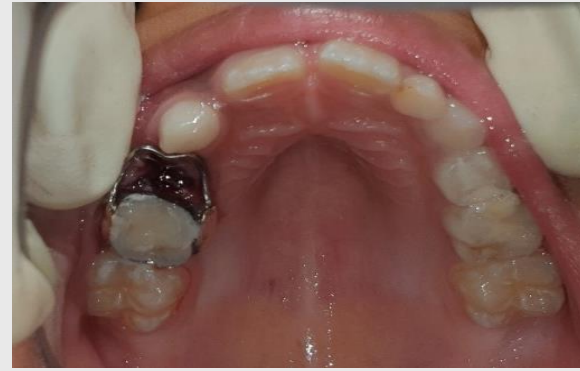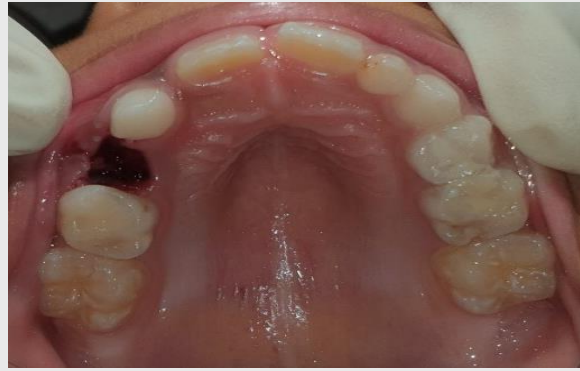21 Days



7 Days

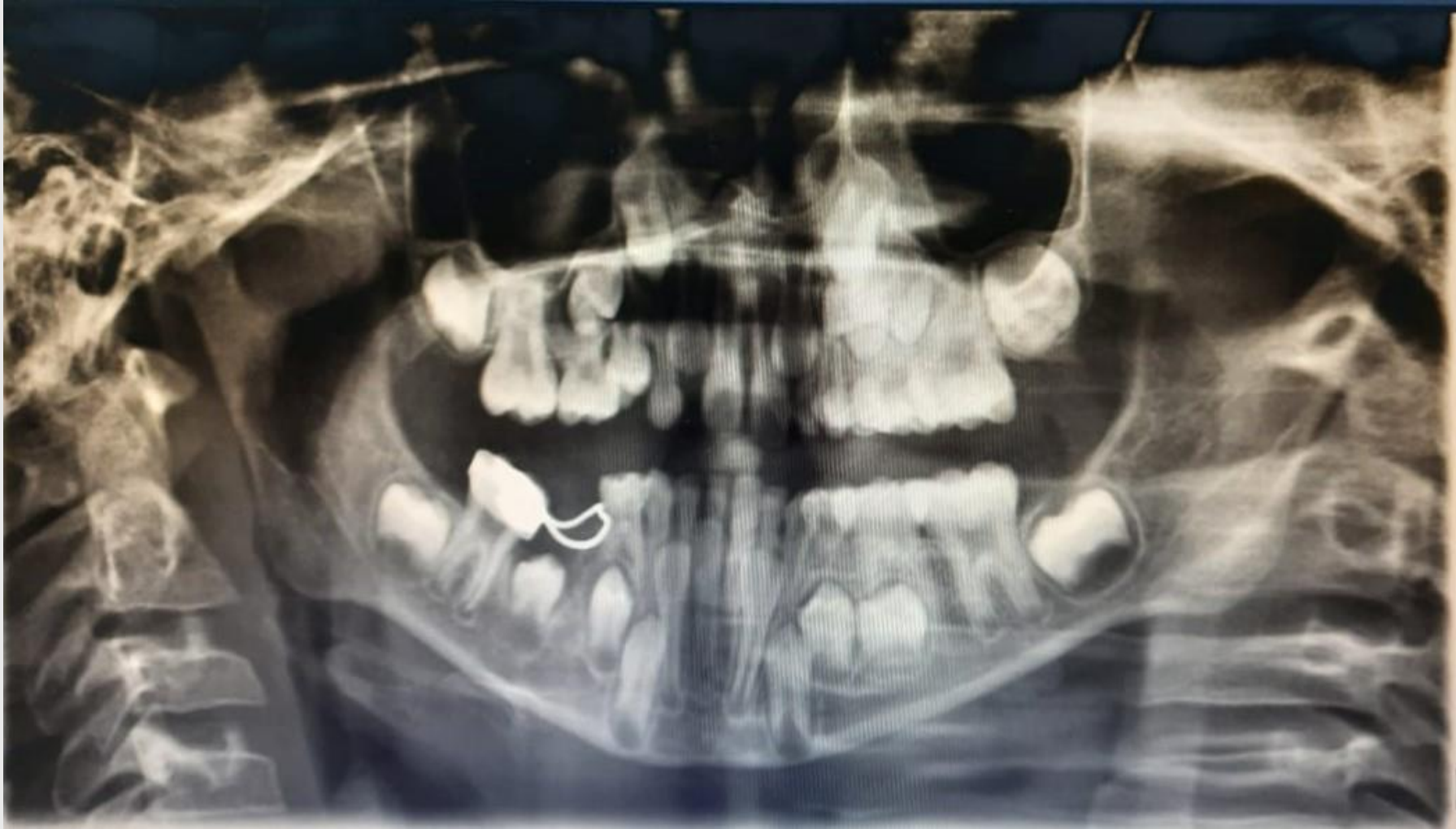


21 Days



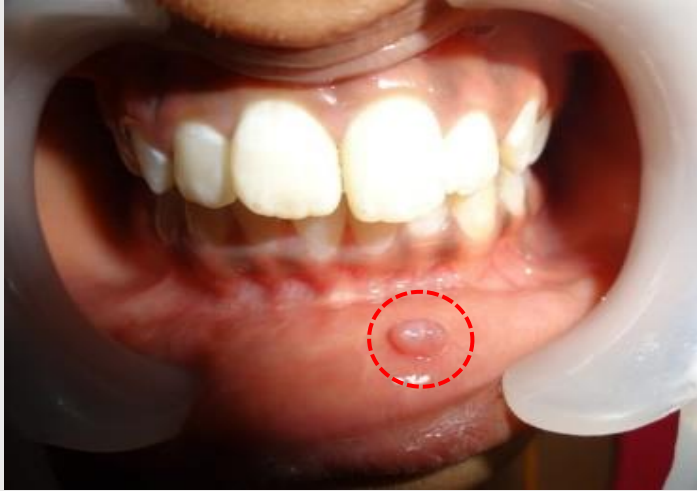BAND AND LOOP SPACE MAINTAINER DELIVERED W.R.T UPPER AND LOWER ARCH

4 MONTH FOLLOW UP

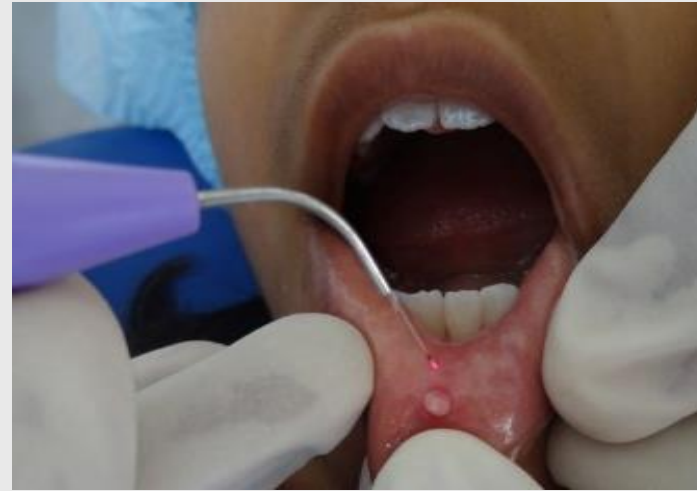

LASER SURGICAL PROCEDURES

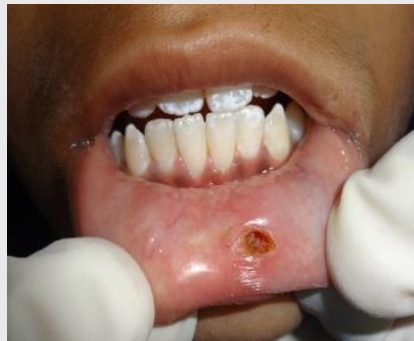LASER MUCOCELE EXCISION



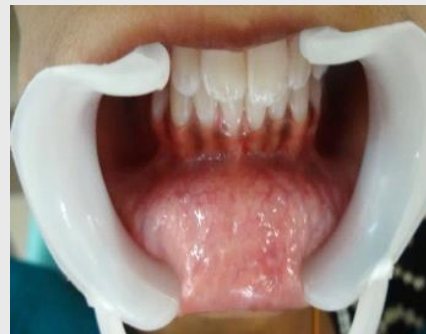Pre op



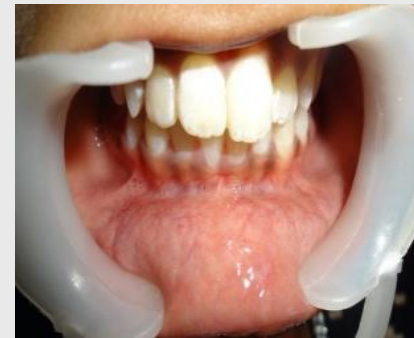Mucocele excision using Soft tissue Diode Laser



Immediate post op

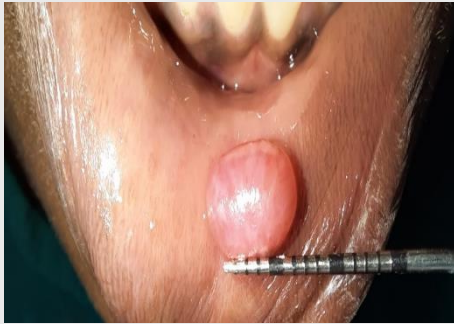
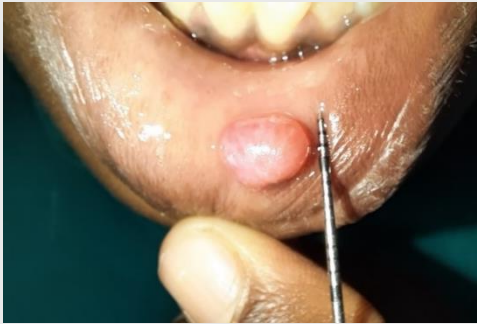
15 days follow up

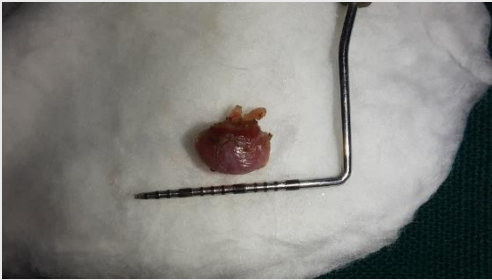

4 month follow up

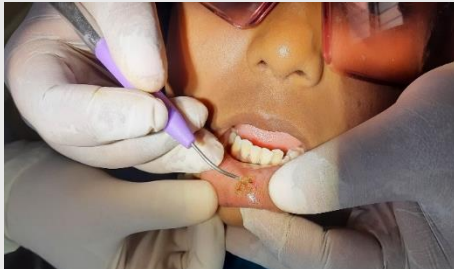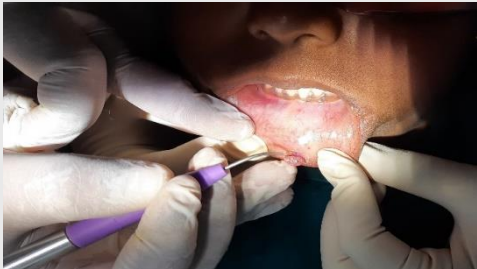LASER EXCISION OF MUCCOCELE



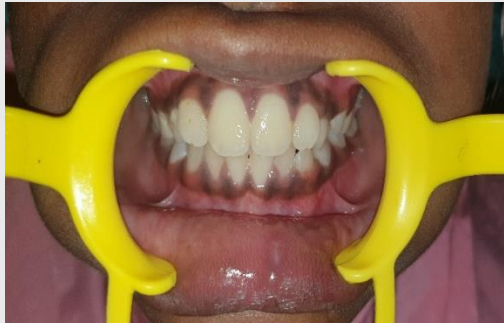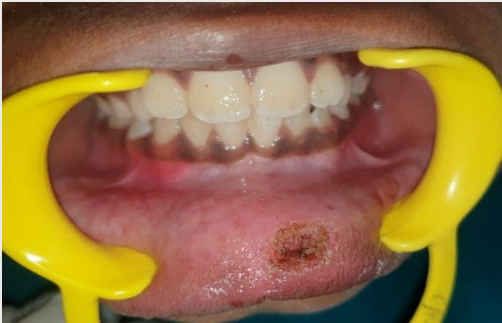PRE-OPERATIVE



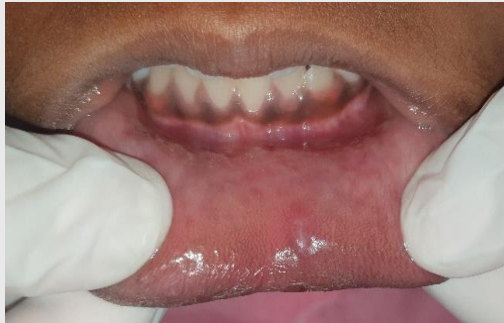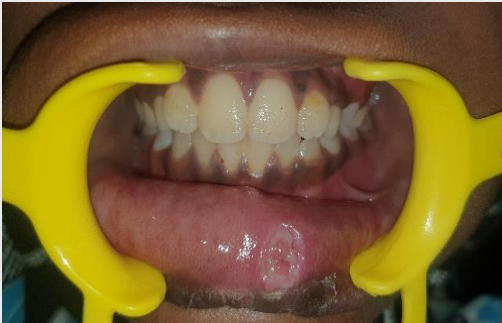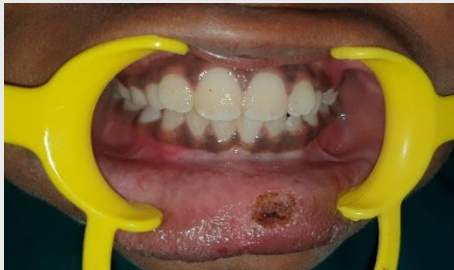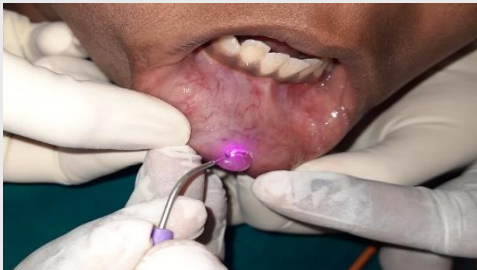EXCISED MUCCOCELE



LASER EXCISION



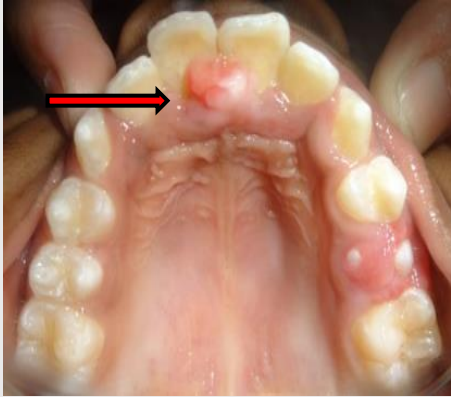
IMMEDIATE POST-OPERATIVE



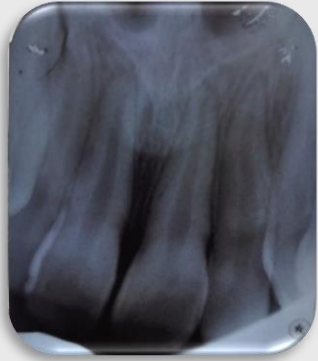1 WEEK FOLLOW UP

1 MONTH FOLLOW UP

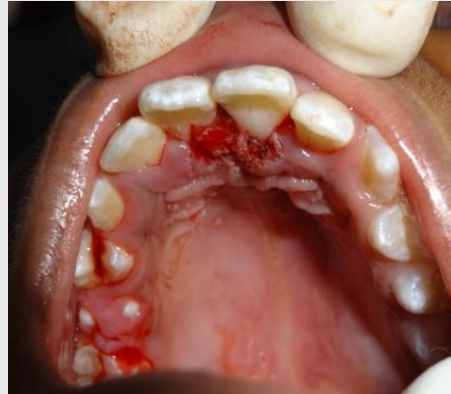LASER FIBROMA EXCISION



Pre op



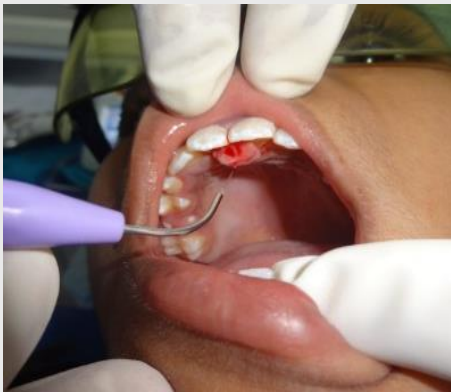Pre op IOPA



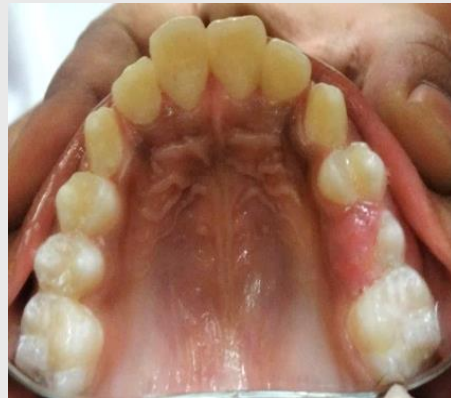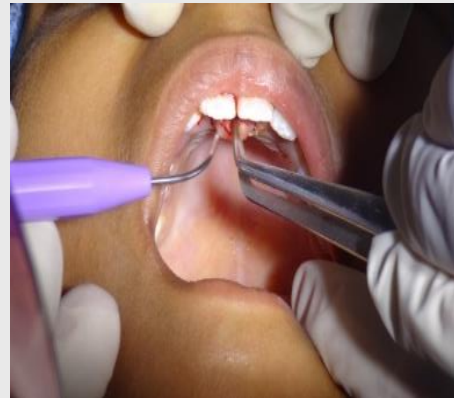Immediate post op



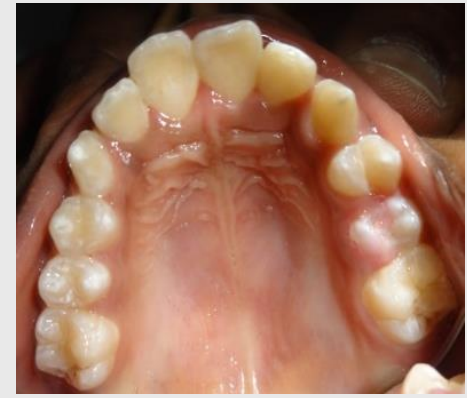Excised tissue



Excision using Soft tissue Diode Laser

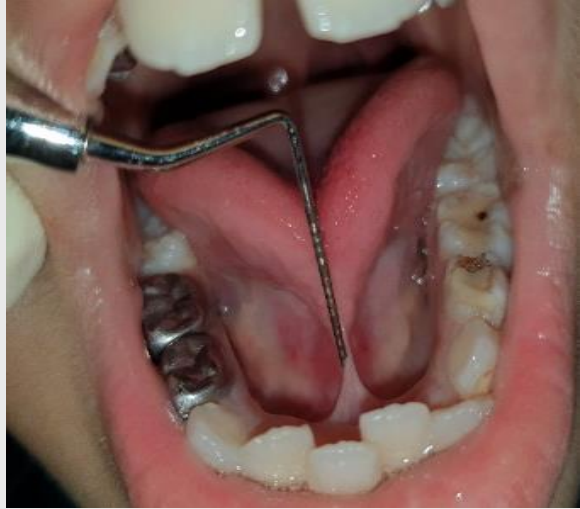
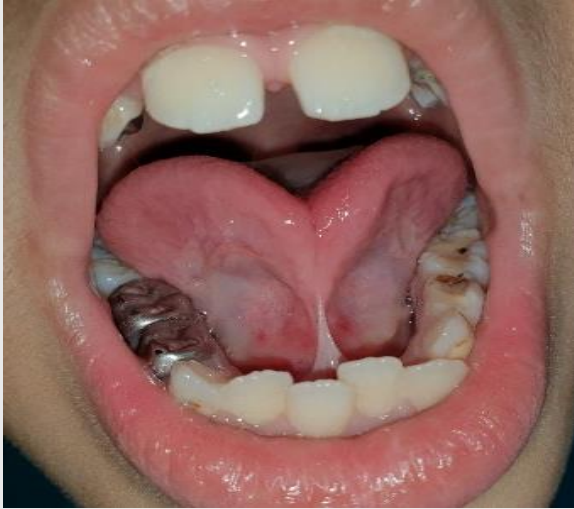
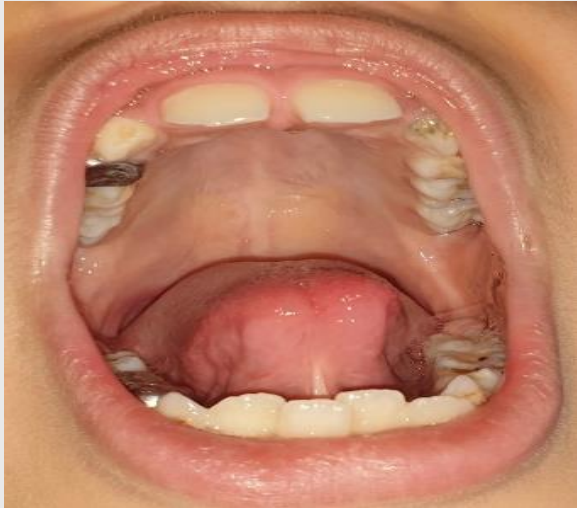15 days follow up

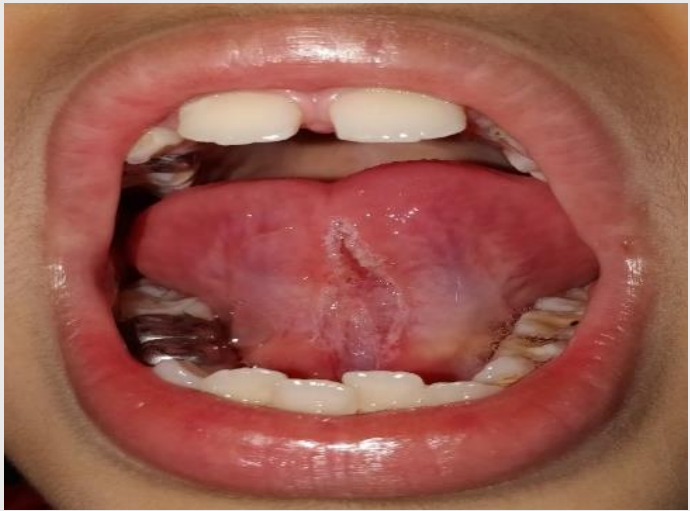

3 month follow up

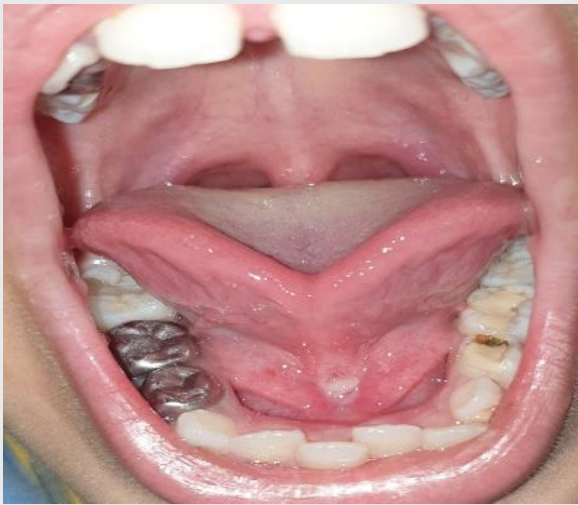LASER LINGUAL FRENECTOMY



PRE-OPERATIVE



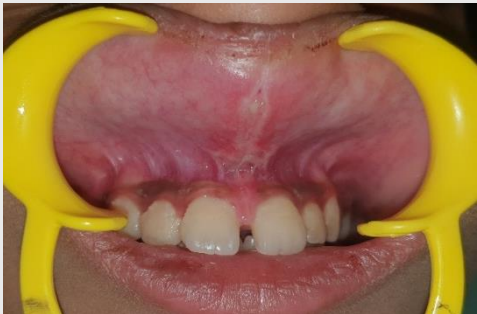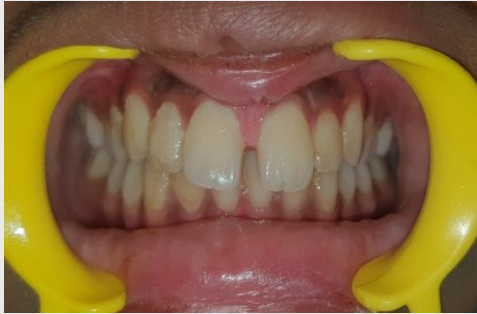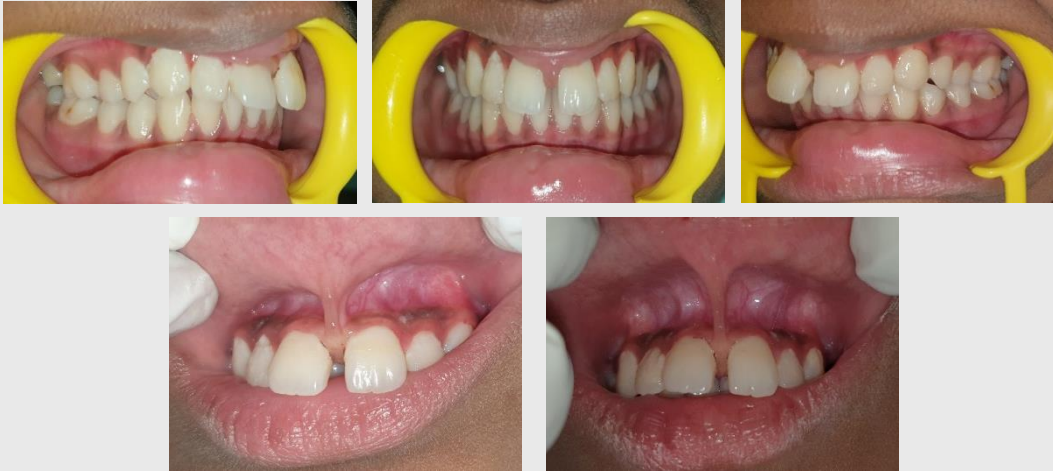POST-OPERATIVE



FOLLOW UP

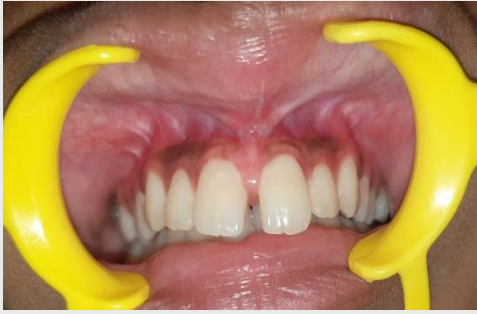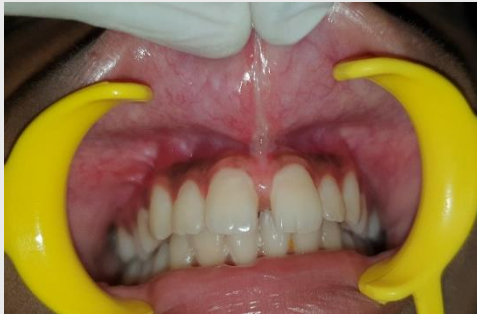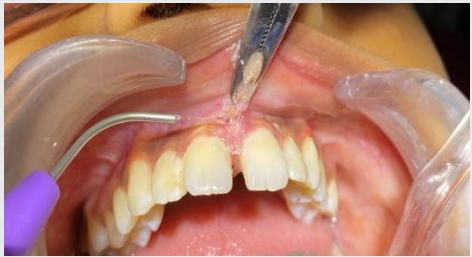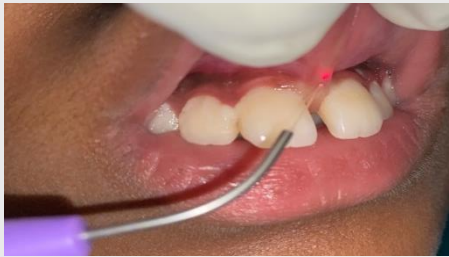LASER LABIAL FRENECTOMY

PRE-OPERATIVE



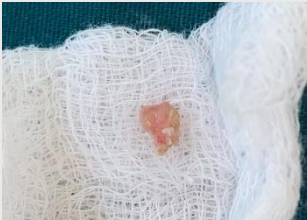1 WEEK FOLLOW UP

LASER EXCISION

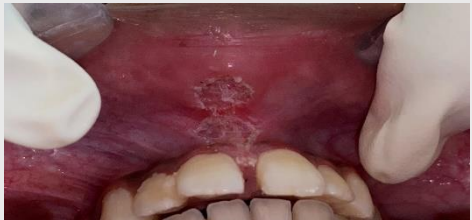

14 DAYS FOLLOW UP

21 DAYS FOLLOW UP



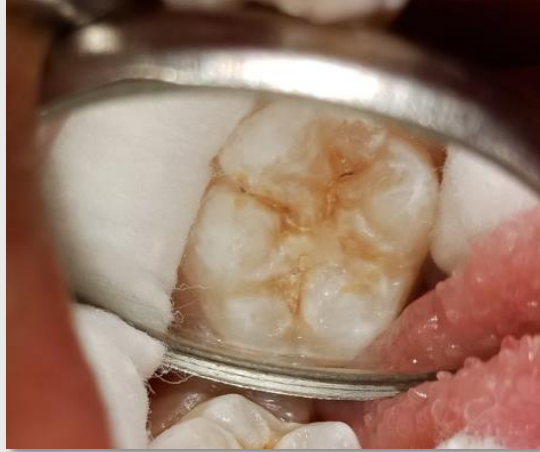EXCISED TISSUE



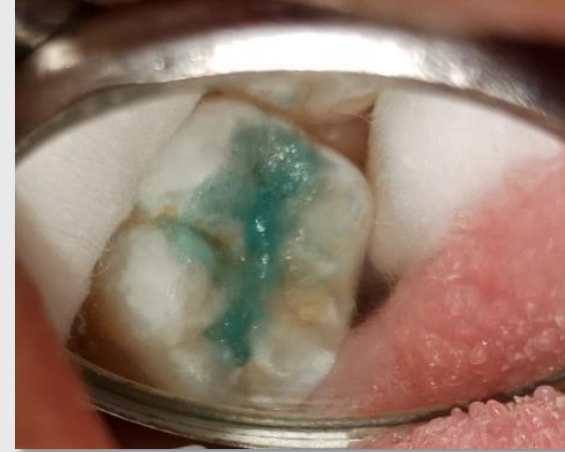IMMEDIATE POST OPERATIVE

**PEDIATRIC PREVENTIVE
DENTISTRY**

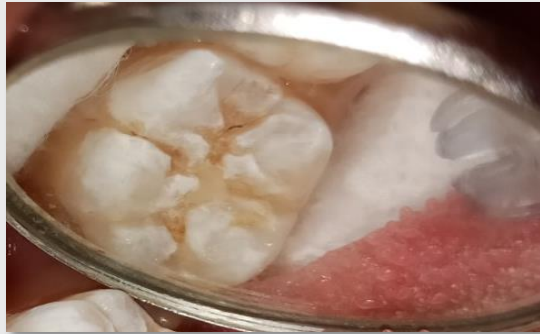PIT AND FISSURE SEALANT APPLICATION



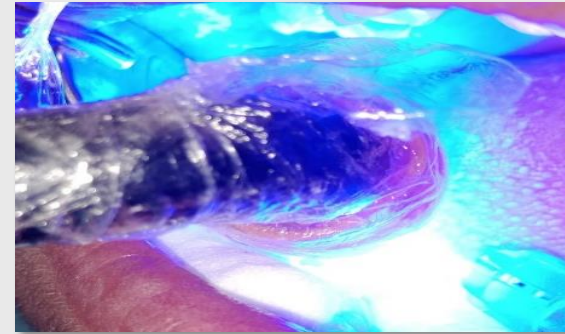Pre Op View



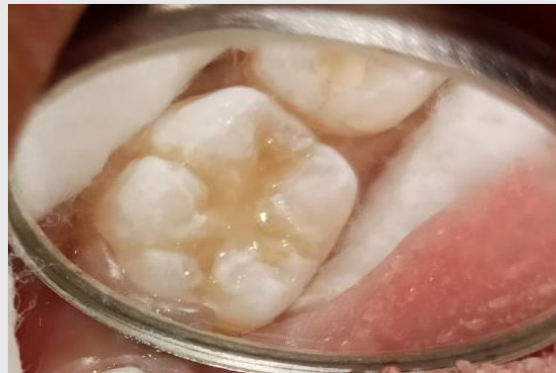Etching



White frosty appearance

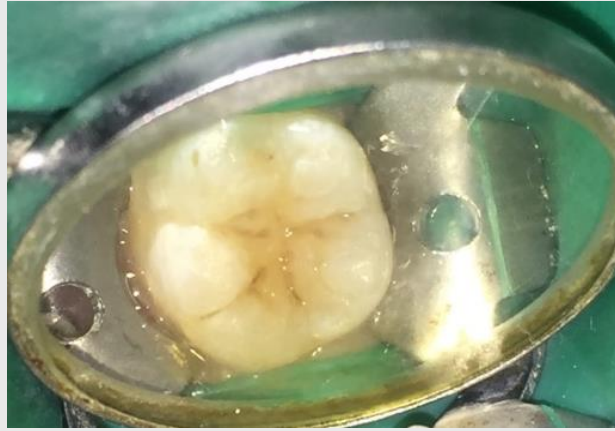


Light curing

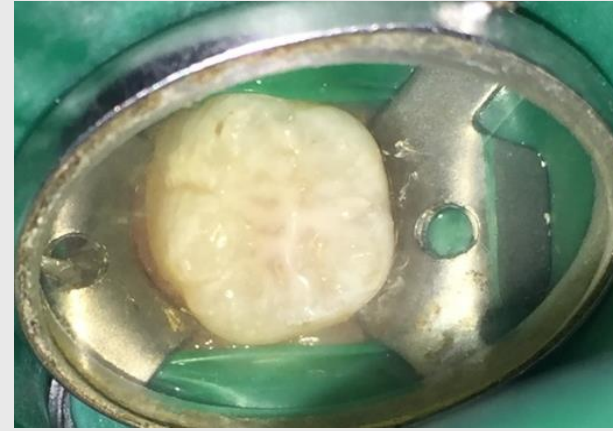


Post Op View

Pit & Fissure sealant application i.r.t 46

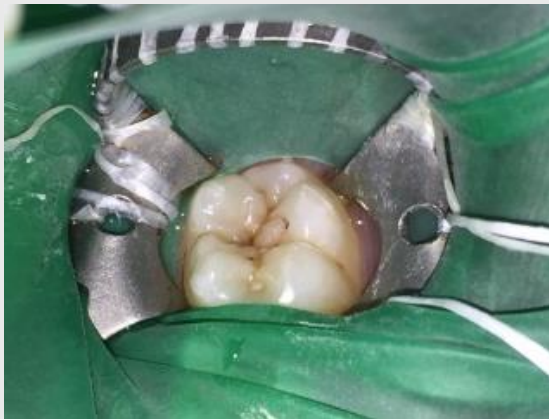

Pre op

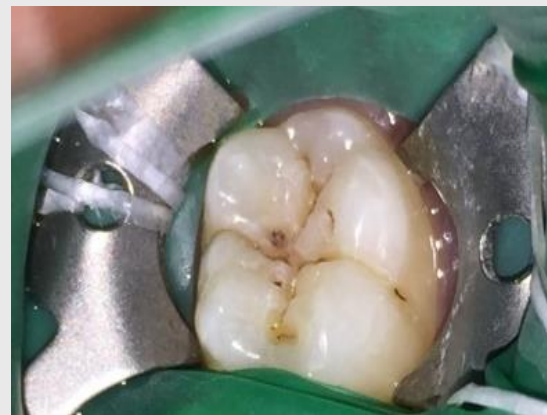

Post op

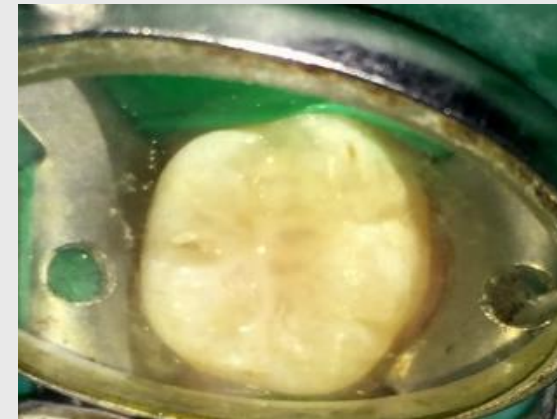
Preventive resin restoration i.r.t 46



Pre op

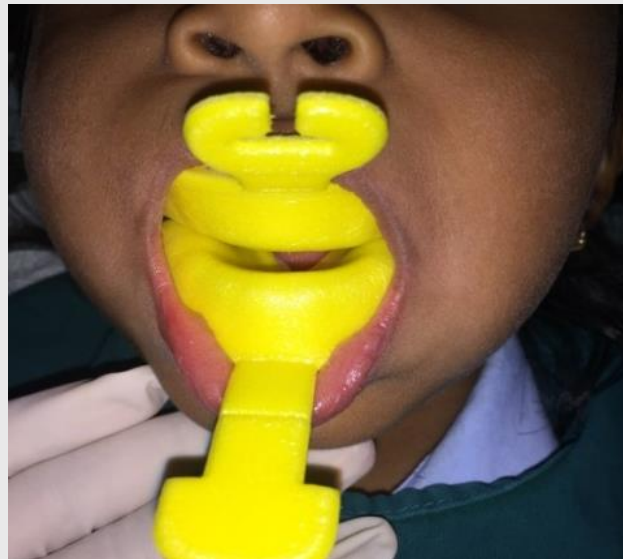
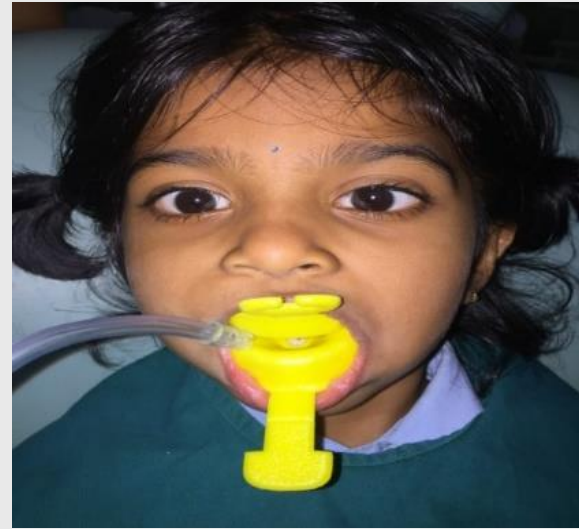
Post preparation

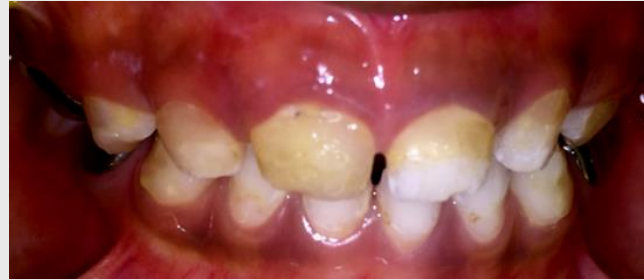

Post op

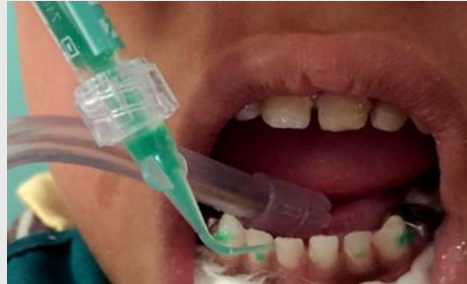Topical fluoride application



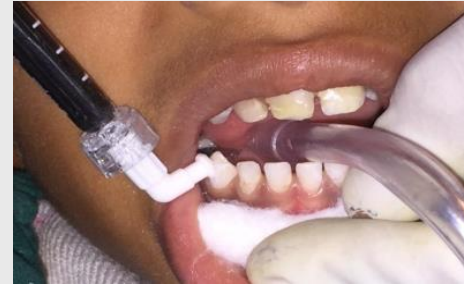Resin infiltration with ICON irt lower incisors and canine



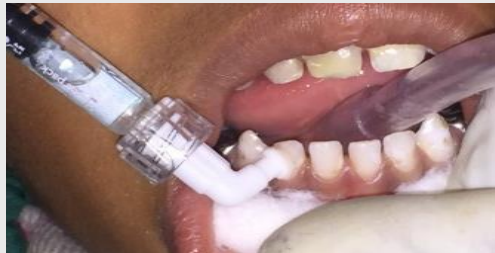Pre op frontal view



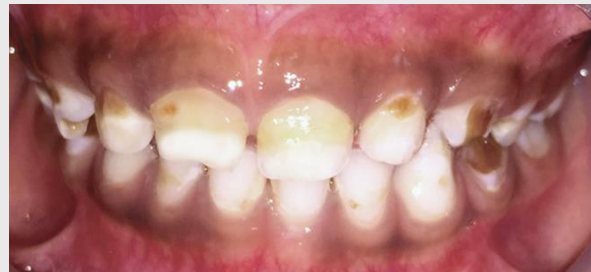Acid etching: 15% HCL



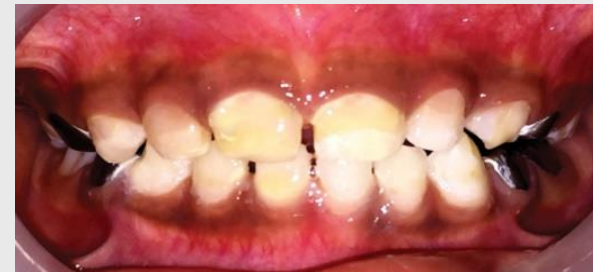Ethanol application



Resin infiltrant application



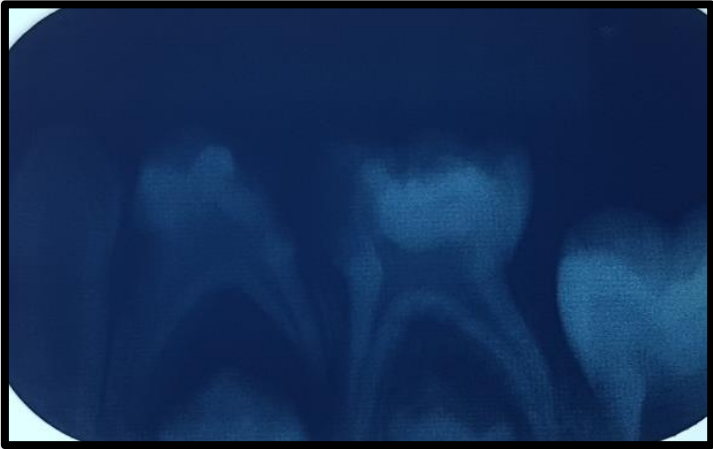
Immediate Post op frontal view



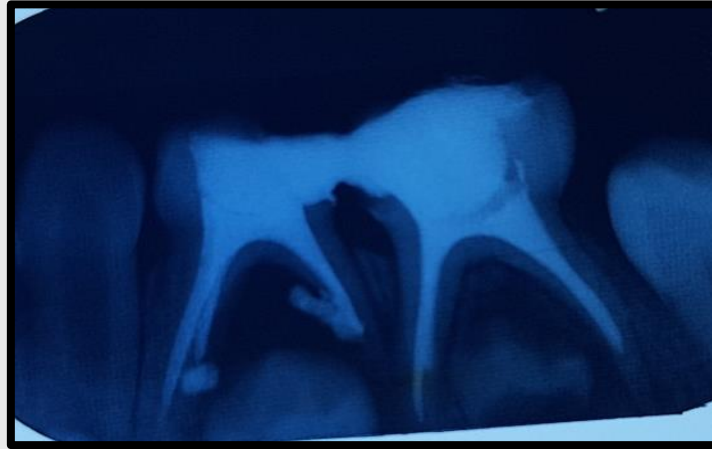At Follow up frontal view

PULP THERAPY

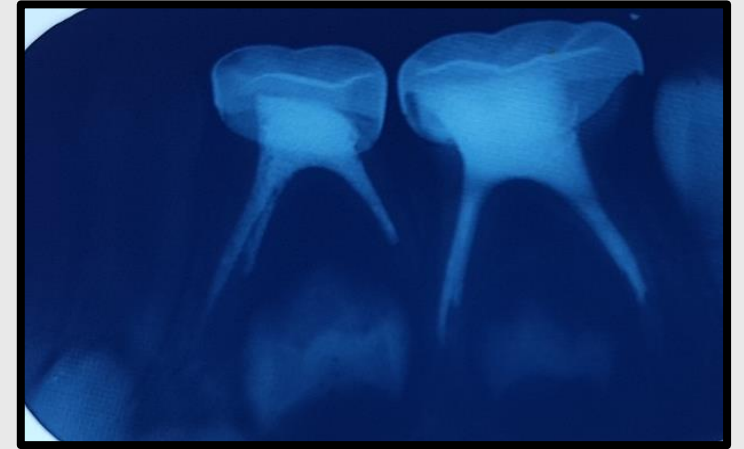
PULPECTOMY



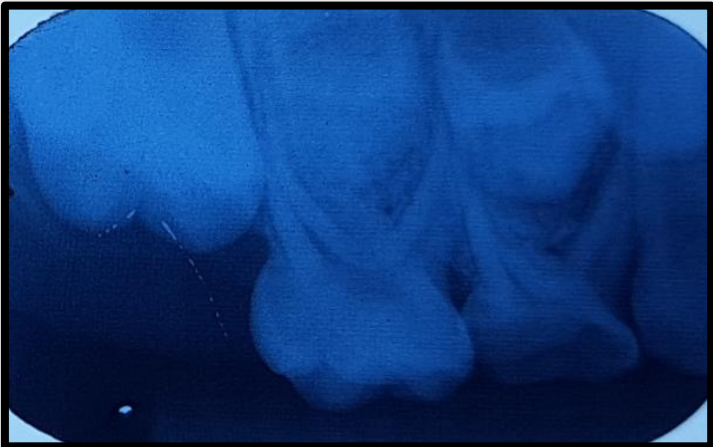PRE OP



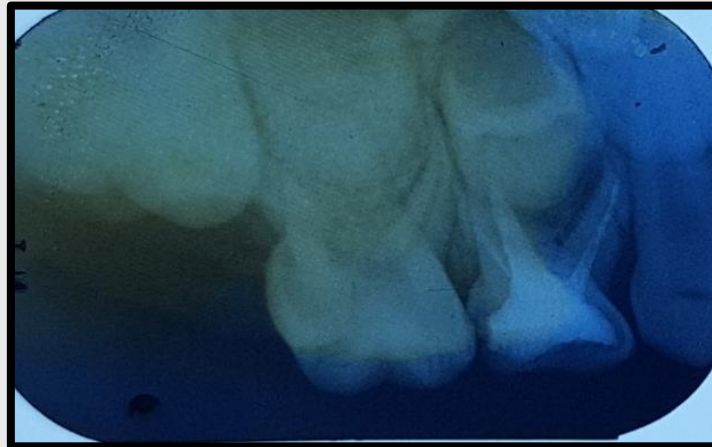
POST OBTURATION



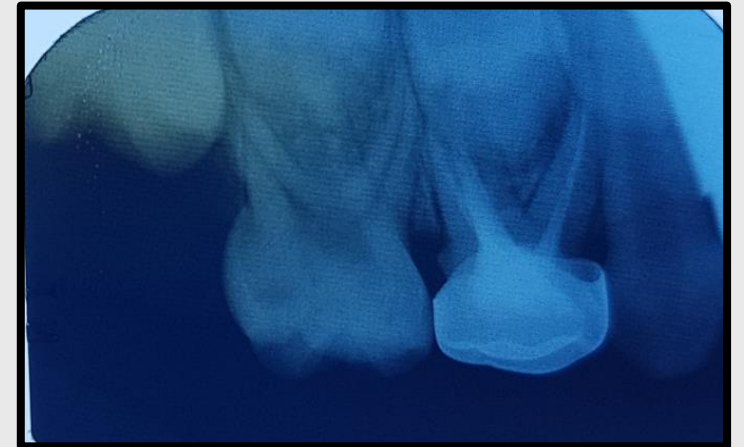SS CROWN CEMENTATION



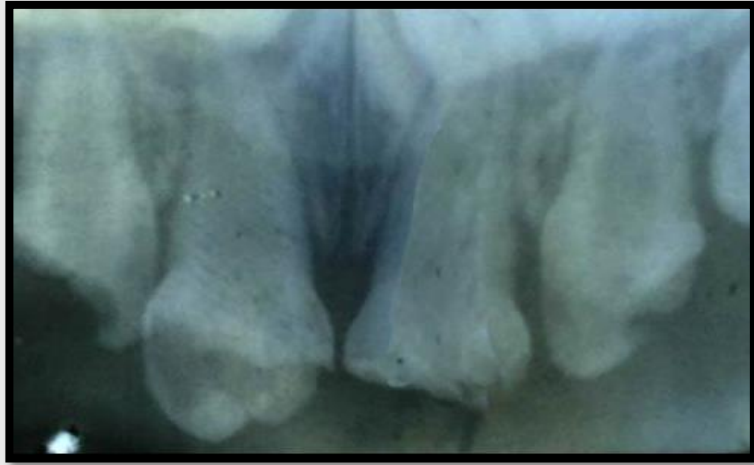PRE OP



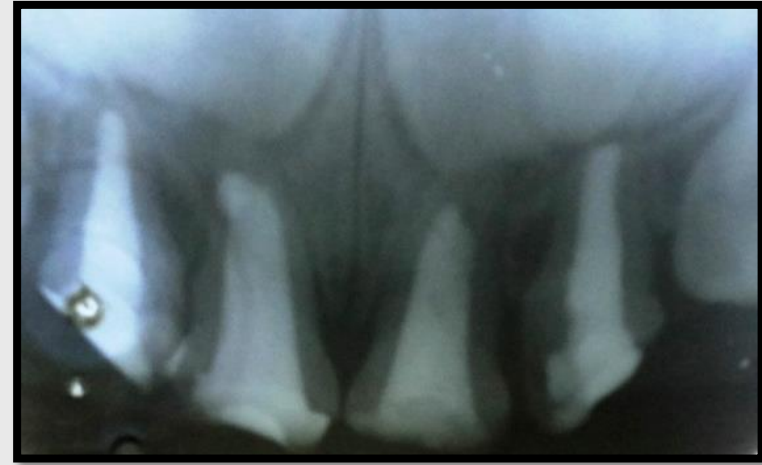POST OBTURATION



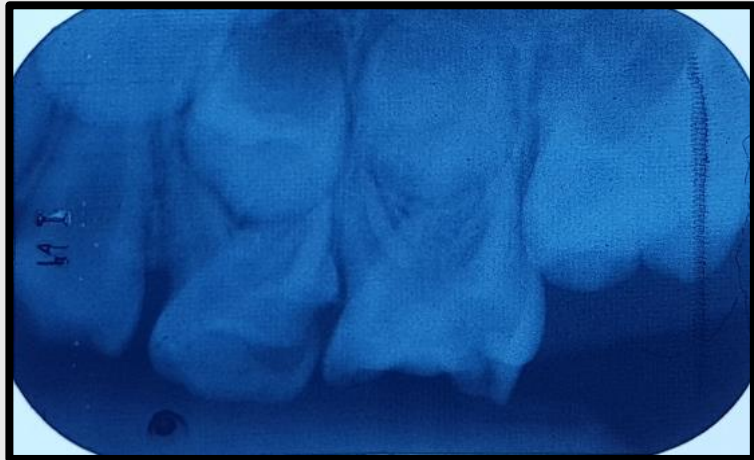
SS CROWN CEMENTATION



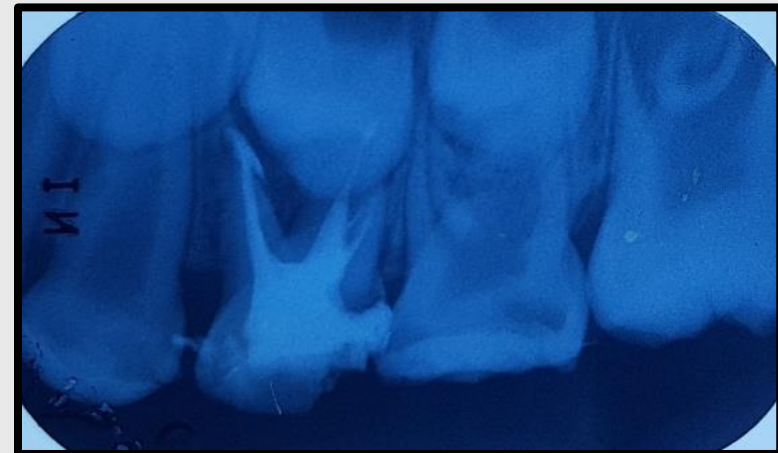
PRE OP



METAPEX OBTURATION



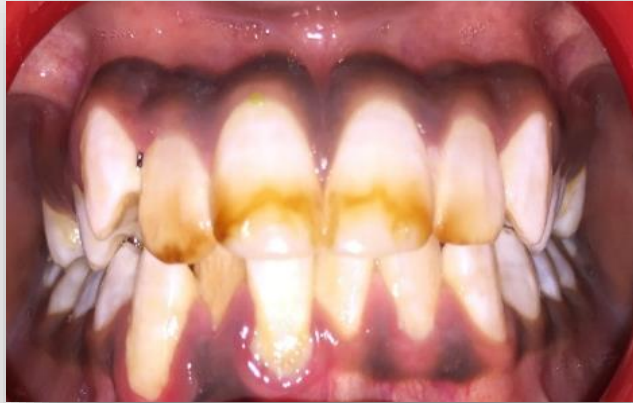PRE OP



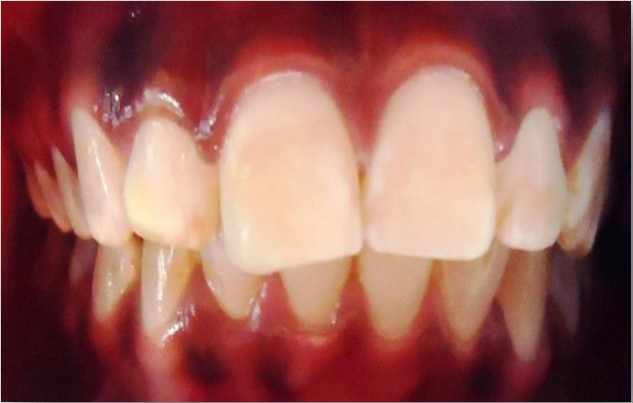METAPEX OBTURATION

TEETH ALBIFICATION

Vital Bleaching

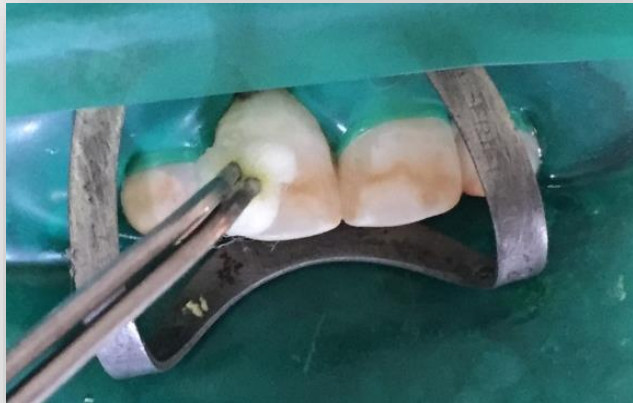

PRE OP

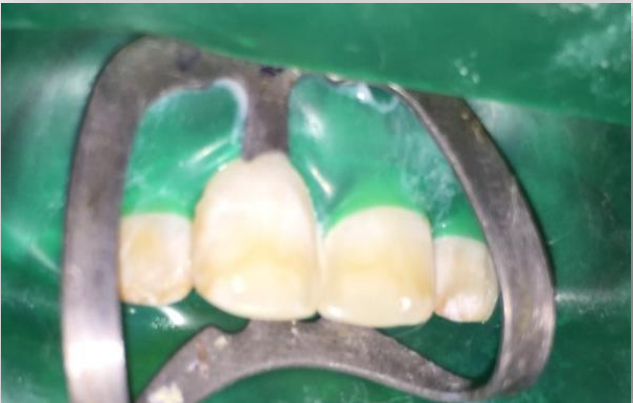

POST OP

CASE 1

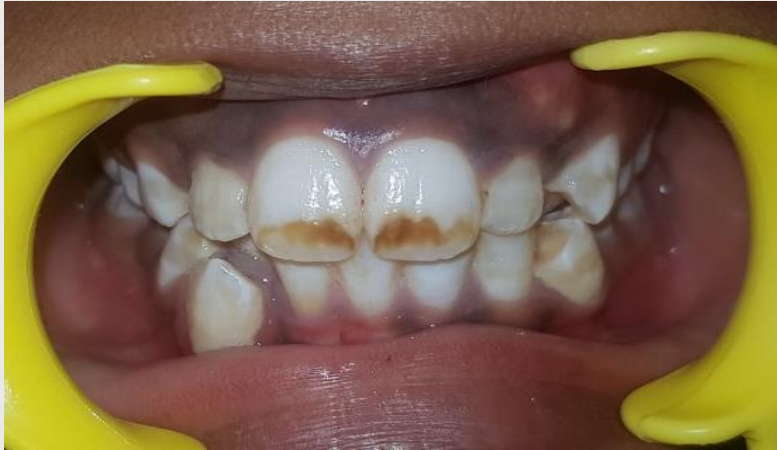

1ST APPLICATION

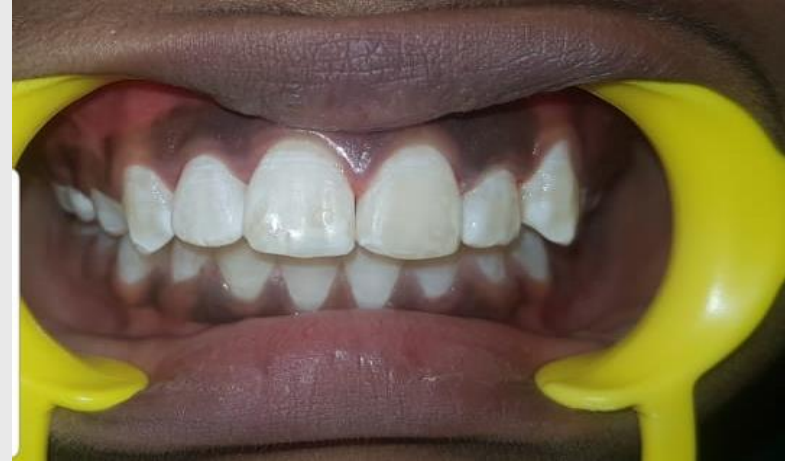

2ND APPLICATION

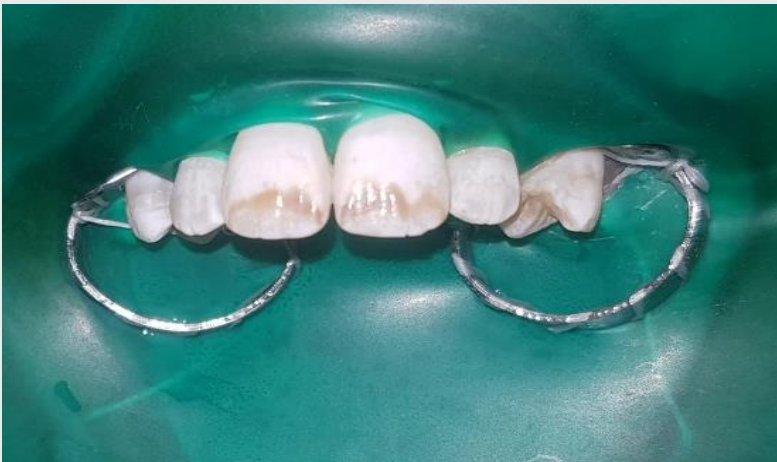CASE 2



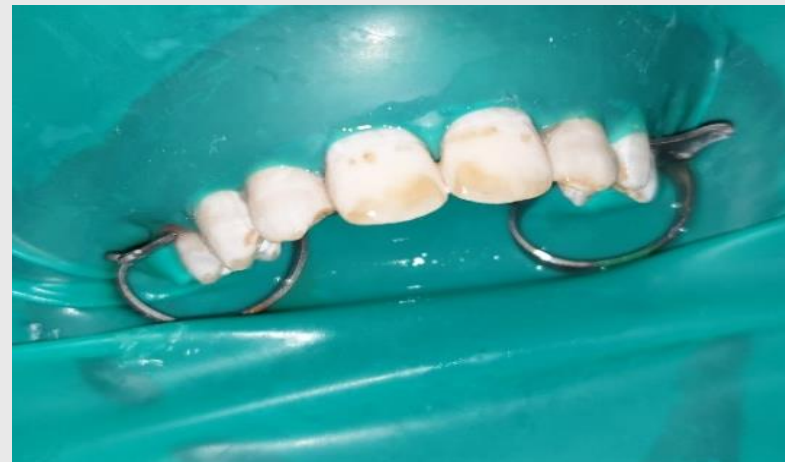PRE OPERATIVE



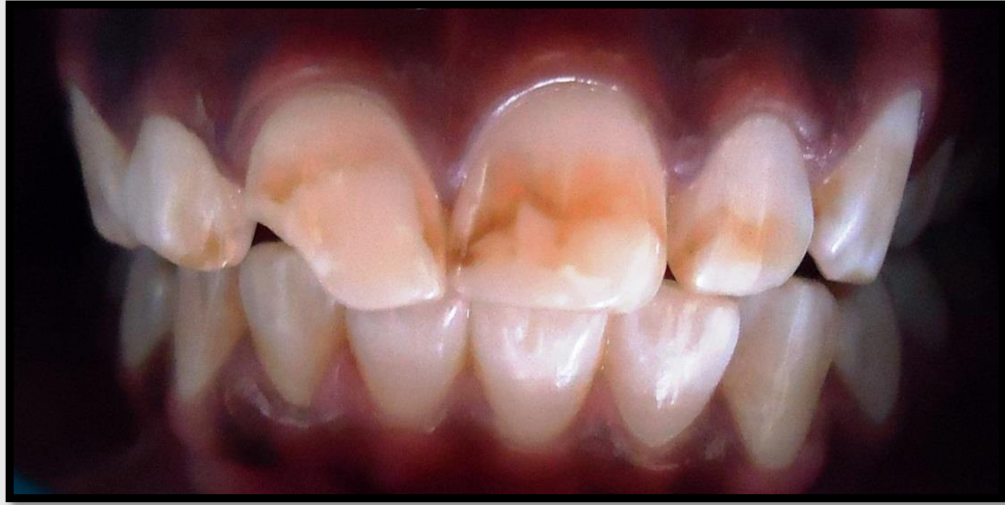POST OPERATIVE



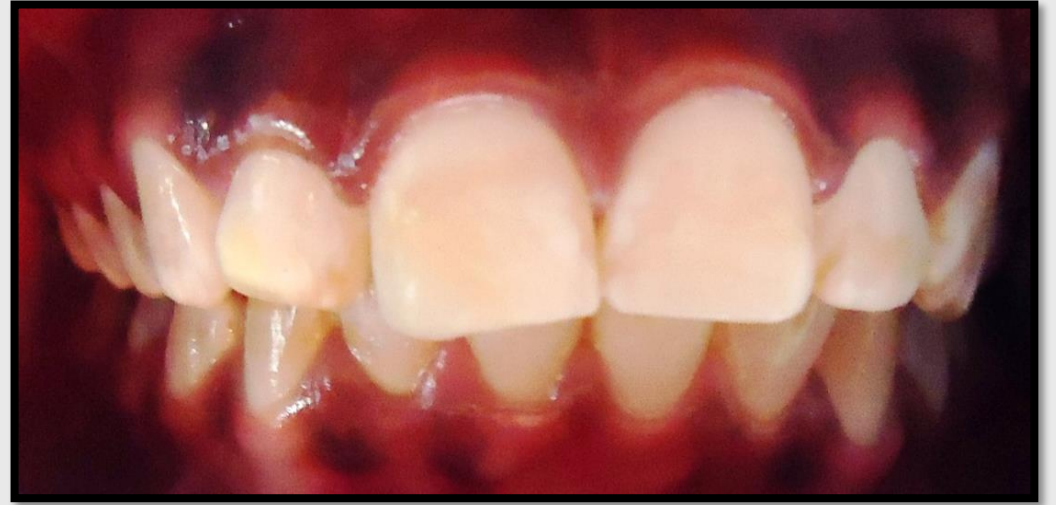POST 1ST APPOINTMENT BLEACHING



POST 2ND APPOINTMENT BLEACHING



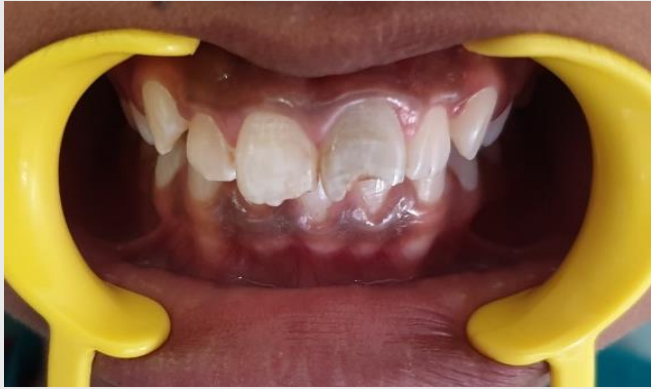Pre Op



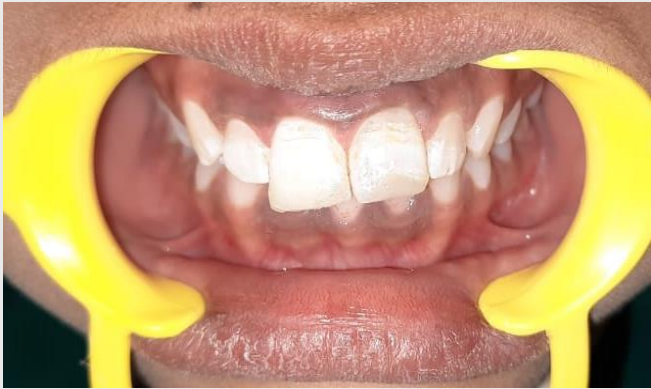Post-op After Vital Bleaching With Mc Innes Solution

CASE 3

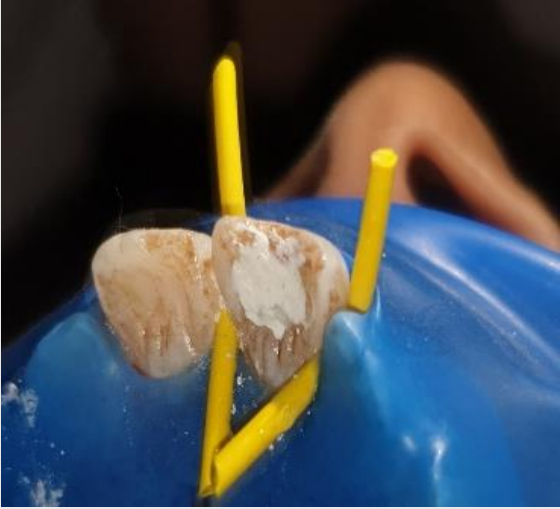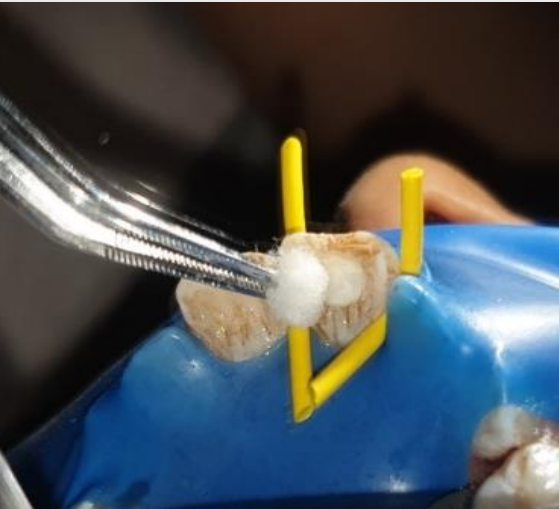
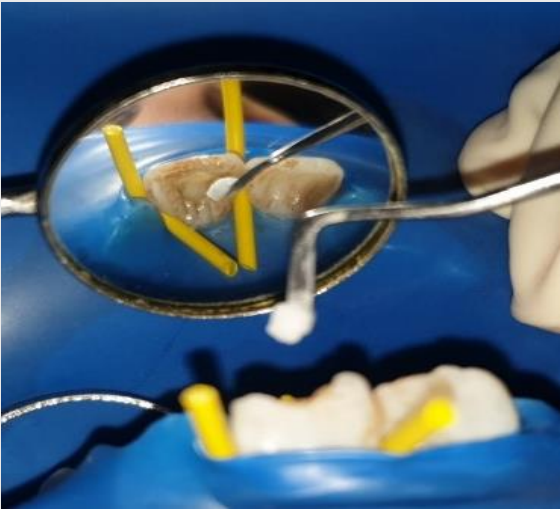
NON-VITAL BLEACHING



PRE-OP



POST-OP



NON-VITAL BLEACHING PROCEDURE